


UN TOUR D'HORLOGE : MON PIRE CAS DE TRAITEMENT ENDOVASCULAIRE DE LA CROSSE

AROUND THE CLOCK: MY WORST CASE OF ENDOVASCULAR ARCH TREATMENT

Frédéric Cochenec, Julien Gaudric,
Thibault Couture, Dorian Verscheure,
Laurent Chiche




Disclosure Statement



I currently have, or have had over the last two years, an affiliation or financial interests or interests of any order with the following companies or I receive compensation or fees or research grants with the following companies:

- **Cook (Proctor)**
- **Philips (Consultant)**
- **Gore (Consultant)**

Cas Clinique 4

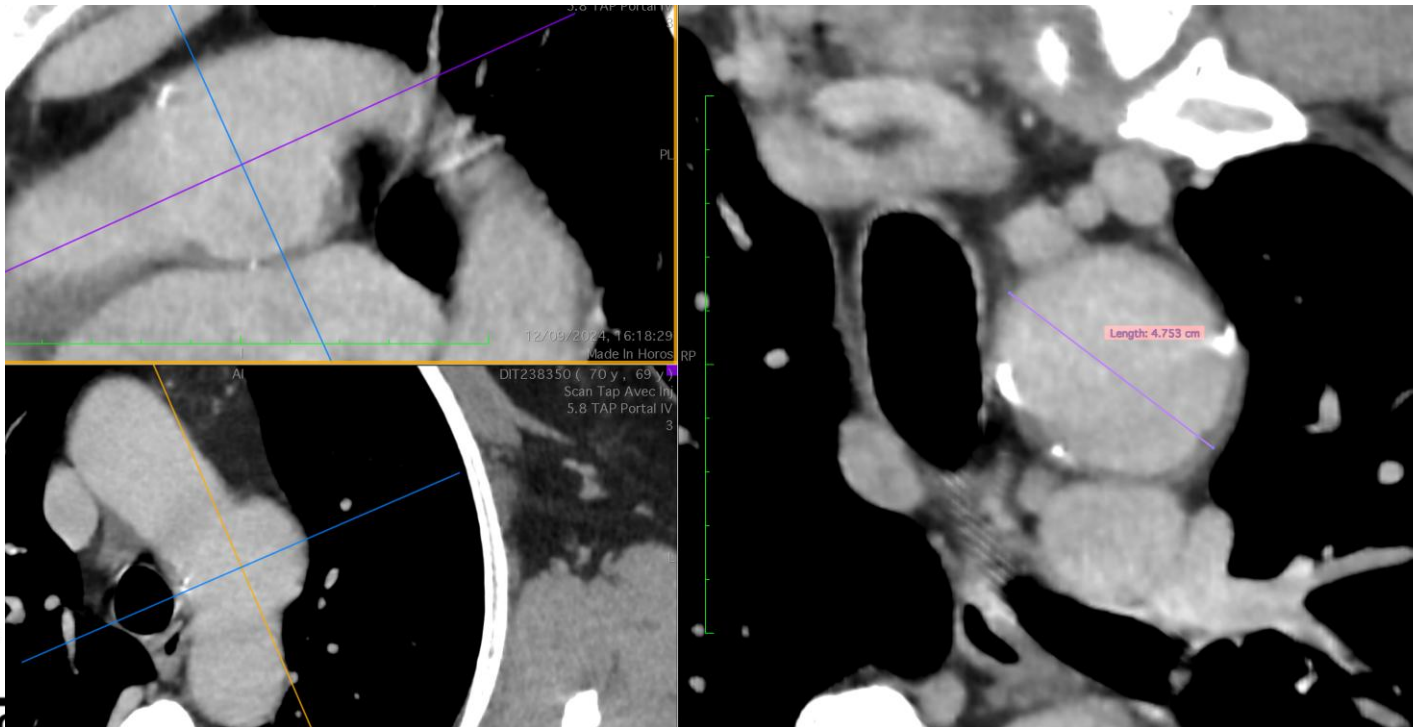


70 years old man, non-revascularizable distal CAD, hypertension, preserved LVEF (77%)

CPAP-treated obstructive sleep apnea

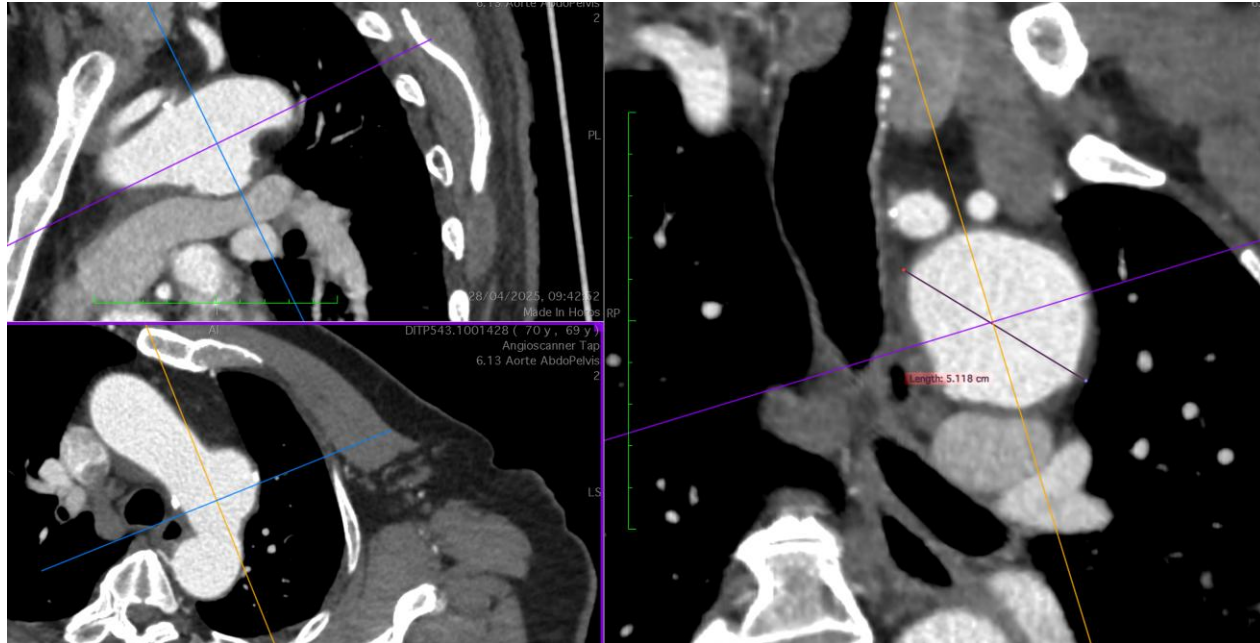

CKD(CrCl 50 mL/min)

supra-aortic duplex scan: Normal

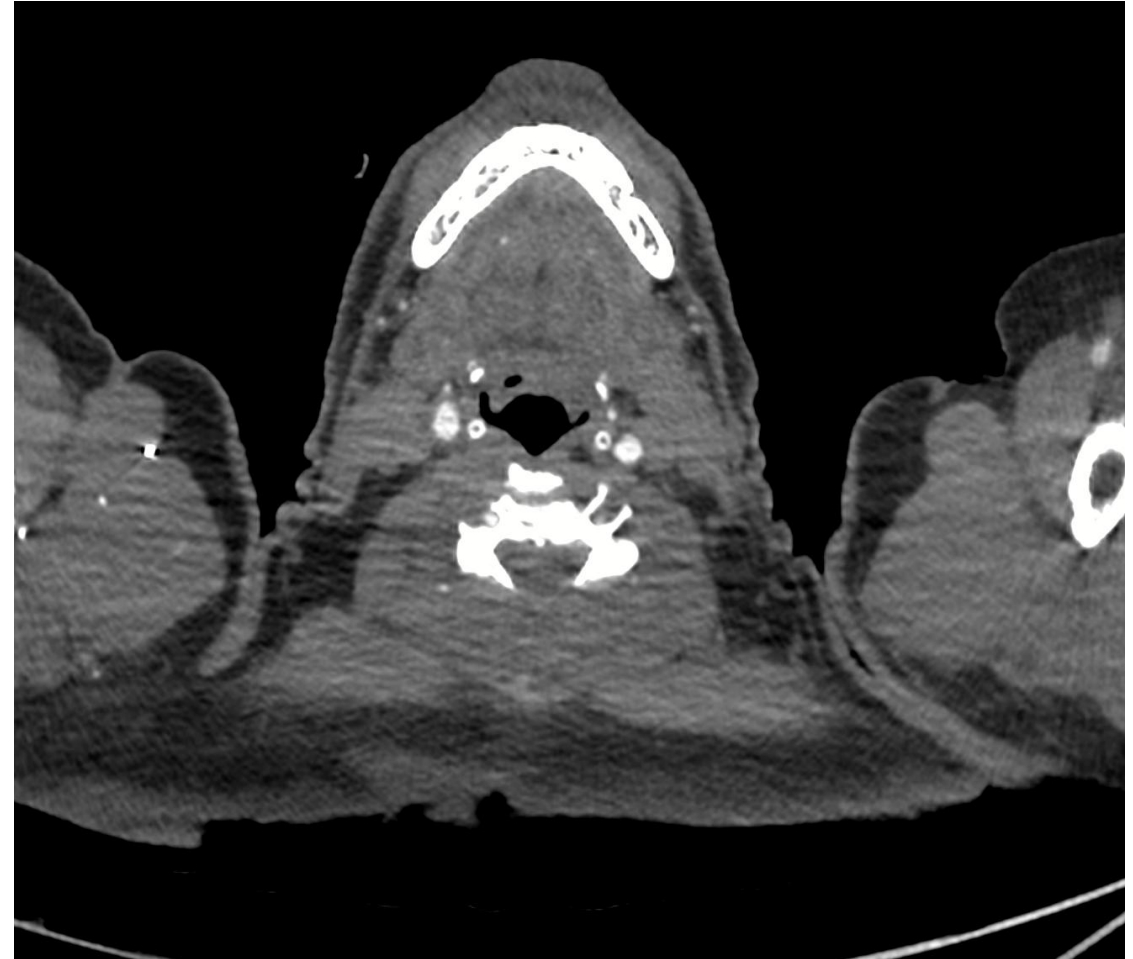


09/2024: 47 mm

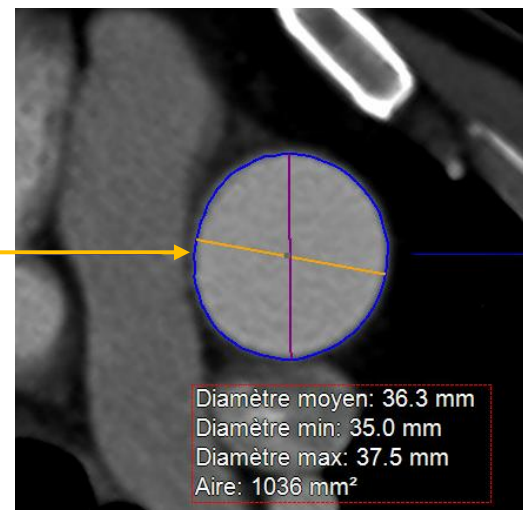
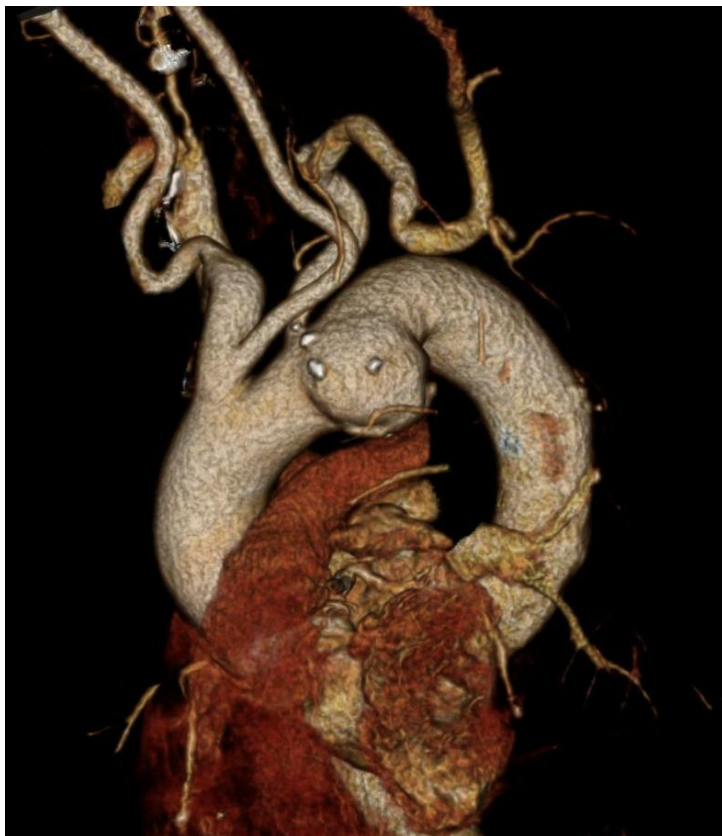
Cas Clinique 4



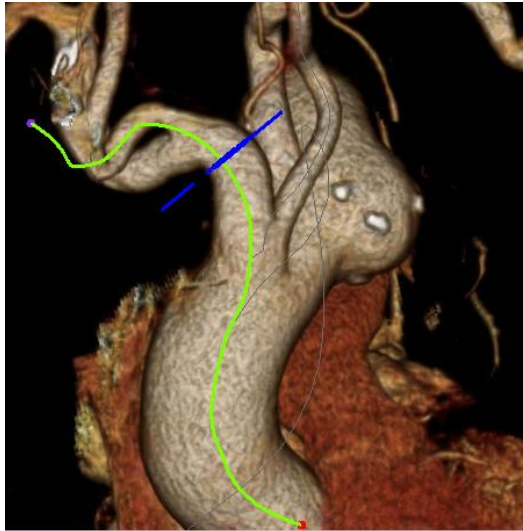

04/2025: 51 mm



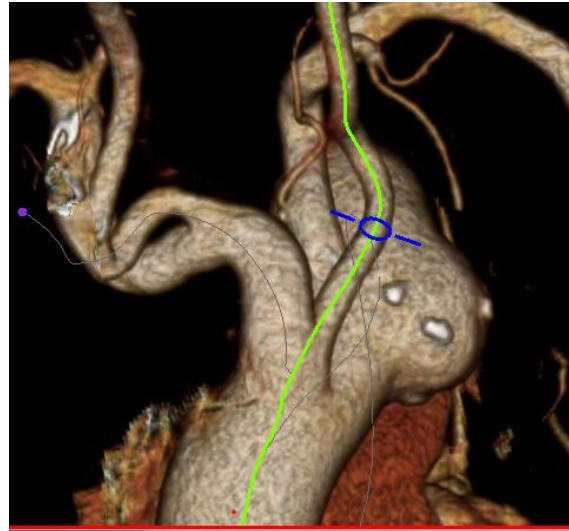
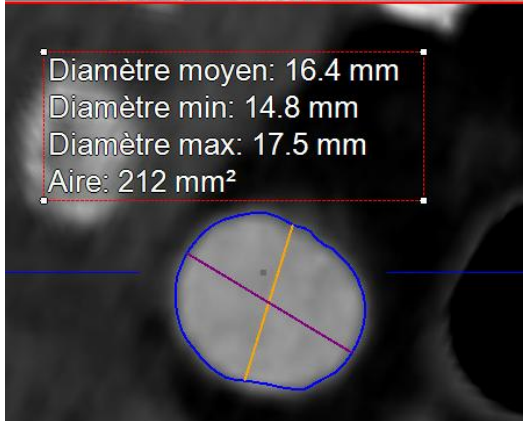
Cas Clinique 4



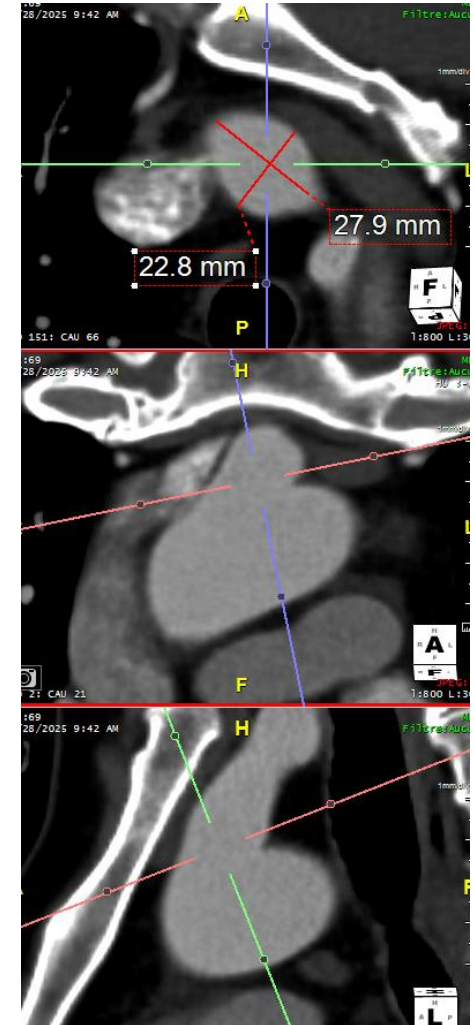
Cas Clinique 4




Diamètre moyen: 16.4 mm
Diamètre min: 14.8 mm
Diamètre max: 17.5 mm
Aire: 212 mm²



Diamètre moyen: 6.82 mm
Diamètre min: 6.58 mm
Diamètre max: 7.01 mm
Aire: 36.5 mm²



Treatment?




Surveillance?

Endo?

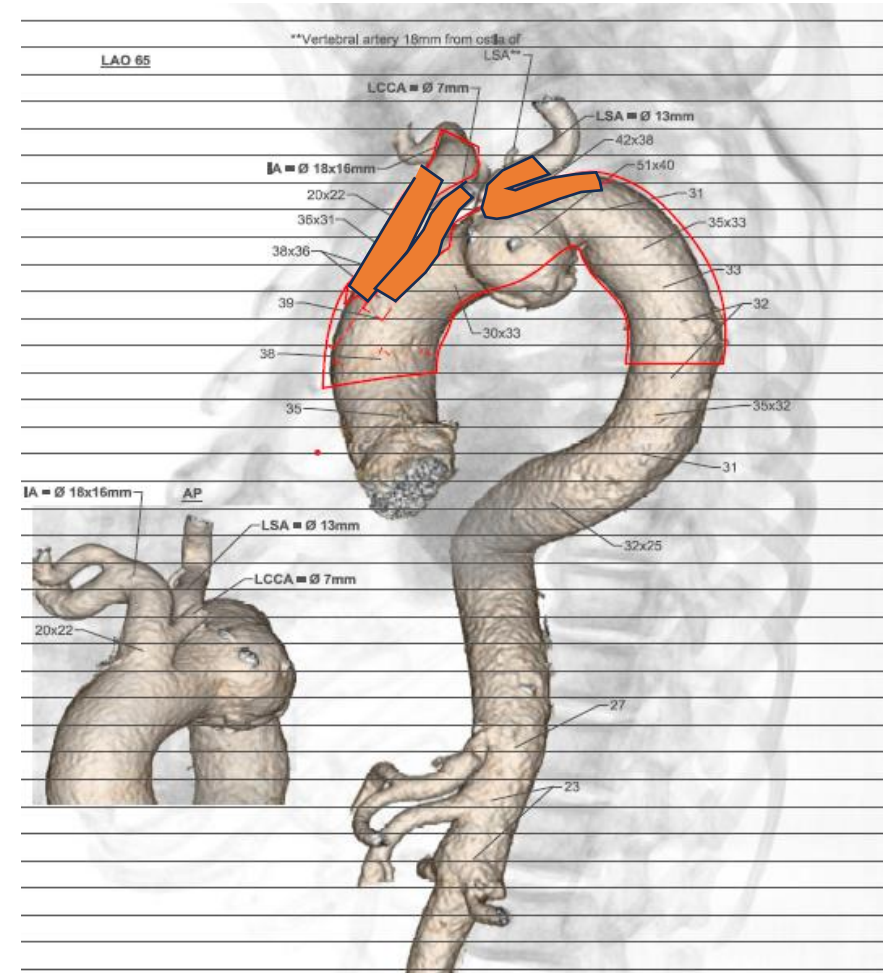
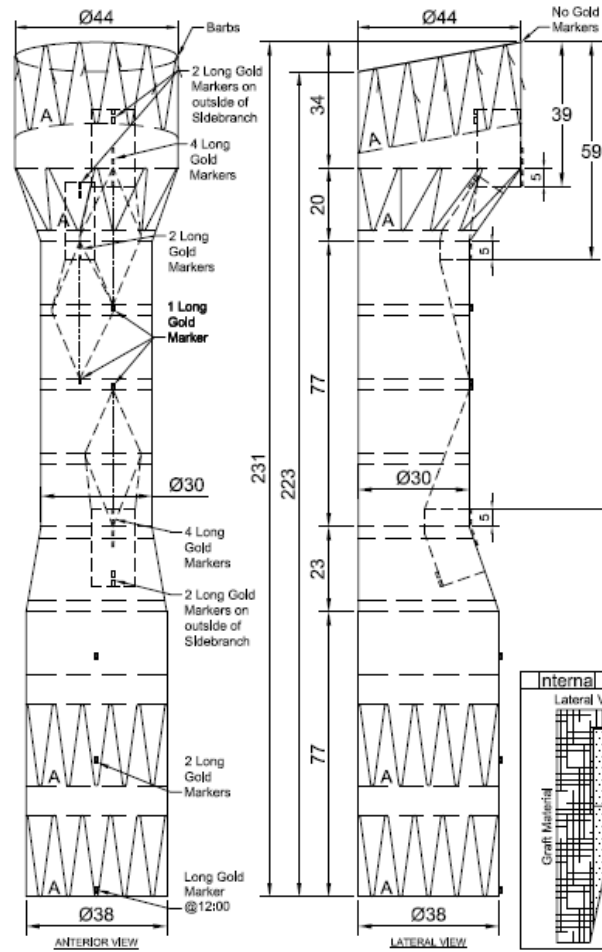
Hybrid?

OR?

Treatment



- CM Cook branch device
- 2 antegrade branch
- 1 retrograde branches






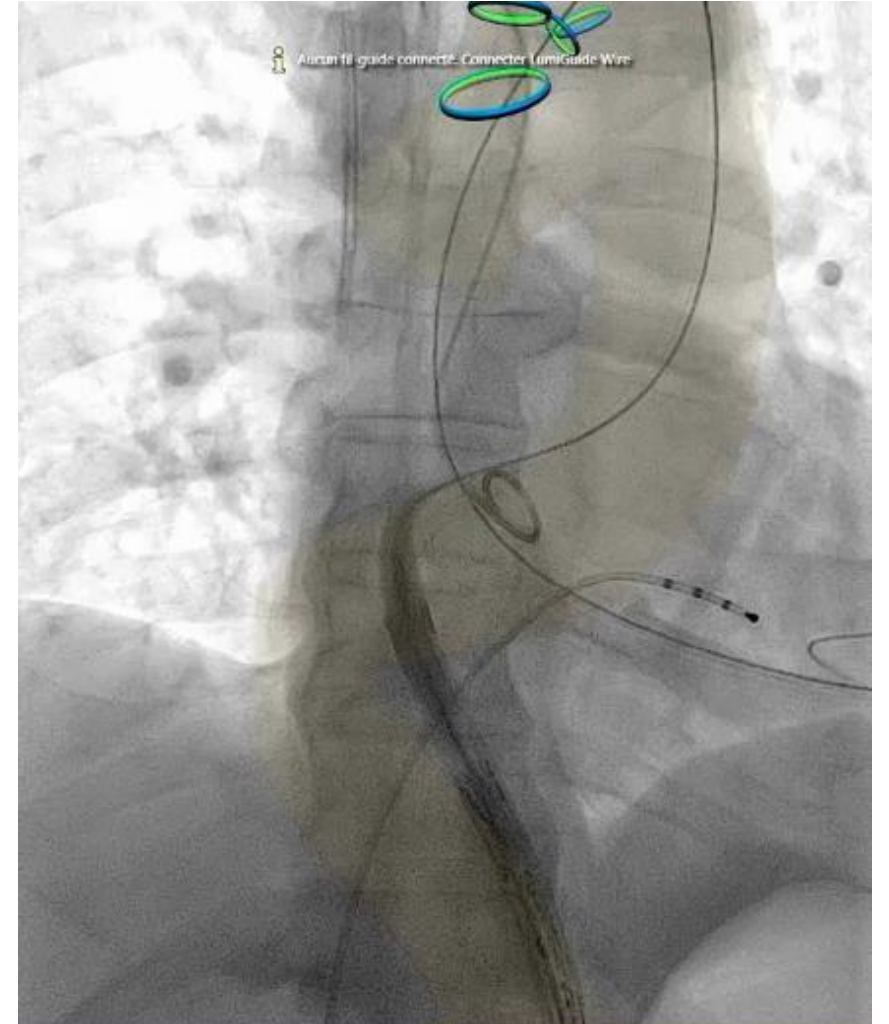
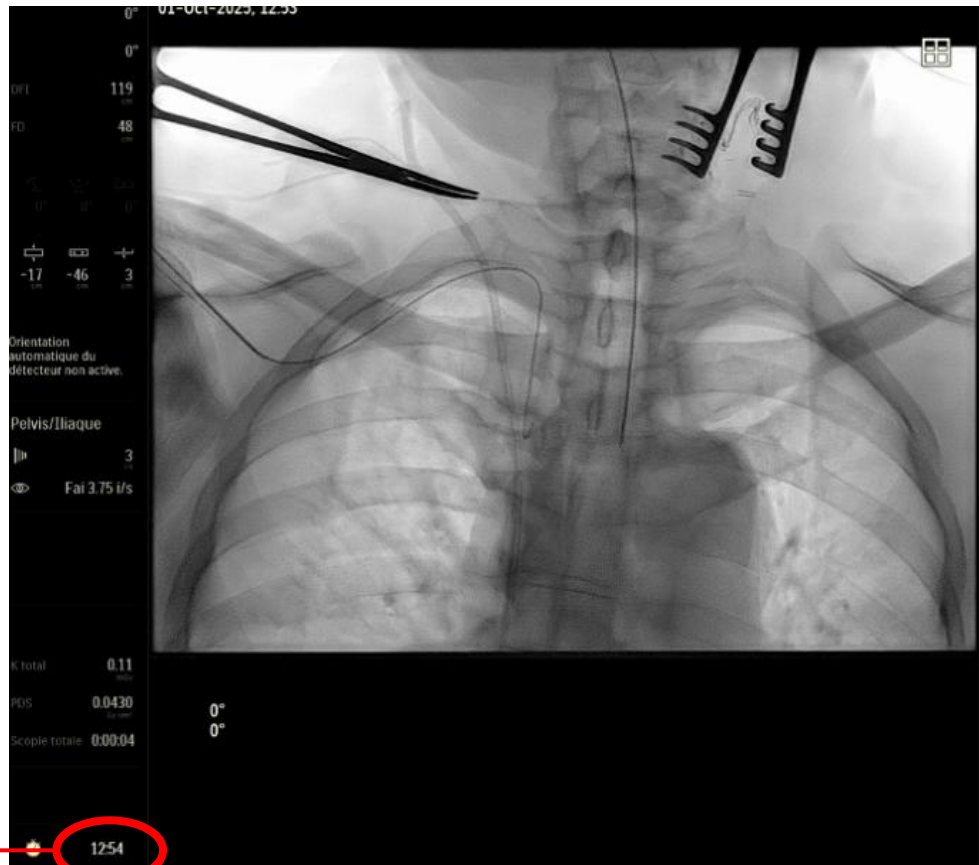
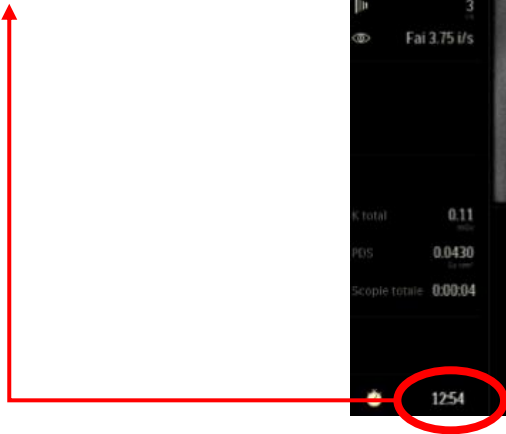
Cjv
WORLD
CHALLENGES & INNOVATIONS IN VASCULAR WORLD

31 MARS
1^{ER} AVRIL **2026**

MÉRIDIEN ÉTOILE
PARIS



Start: 12.54

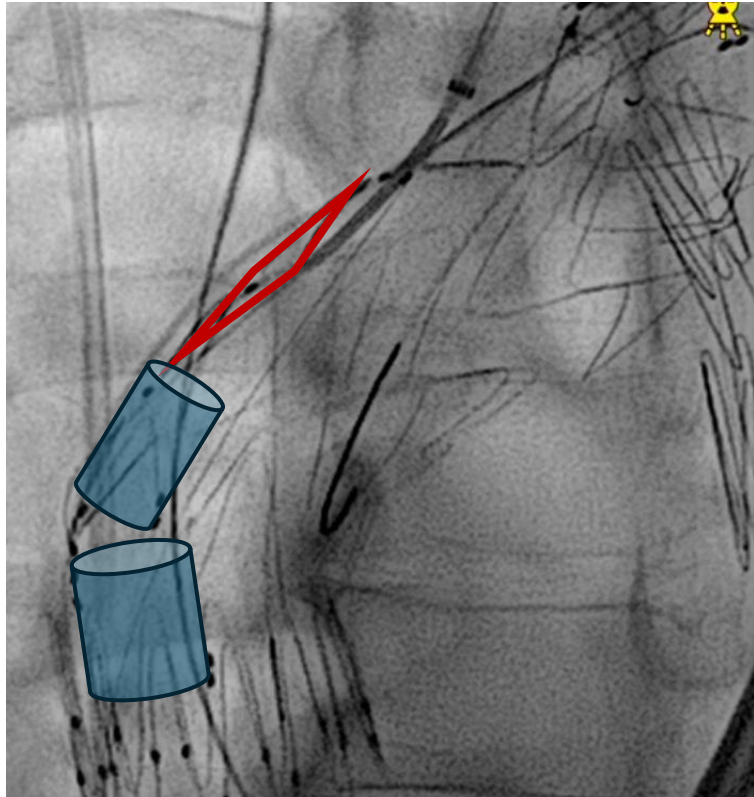





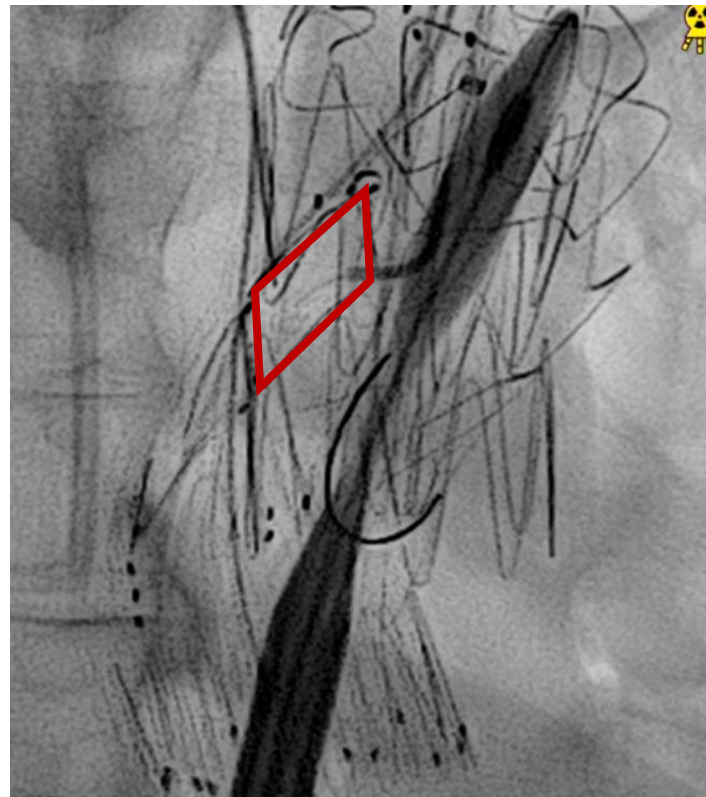
Cjv
WORLD
CHALLENGES & INNOVATIONS IN VASCULAR WORLD

31 MARS
1^{ER} AVRIL **2026**


MÉRIDIEN ÉTOILE
PARIS



Branch for innominate artery : OK



Branch for left carotid artery: canulation failure with conventional catheters (BER, KMP, Vanschie)

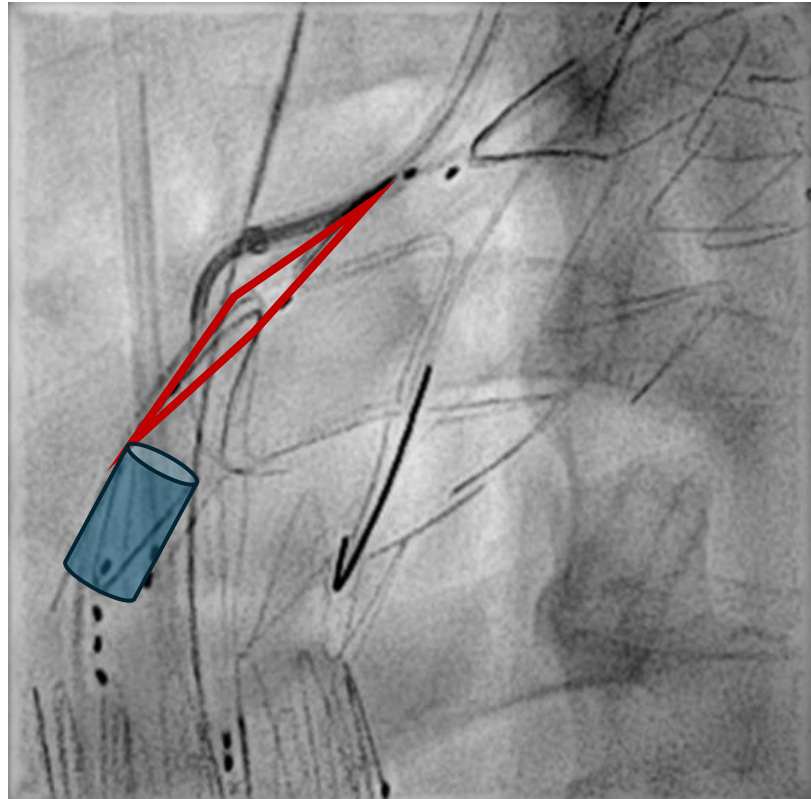





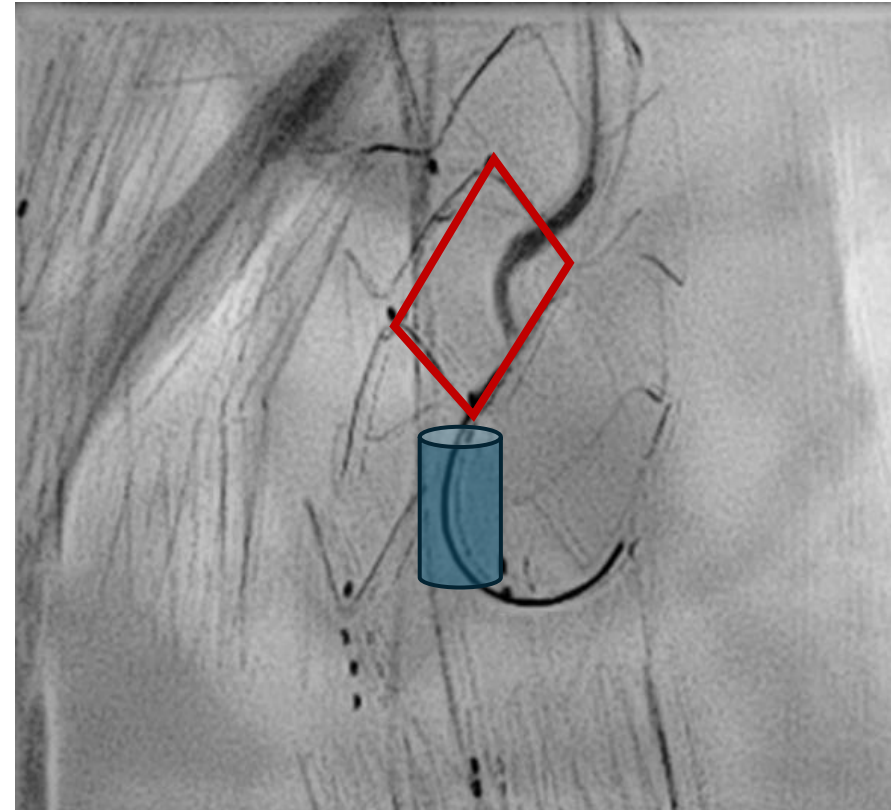
Cjv
WORLD
CHALLENGES & INNOVATIONS IN VASCULAR WORLD

31 MARS
1^{ER} AVRIL **2026**

MÉRIDIEN ÉTOILE
PARIS



17.13 pm



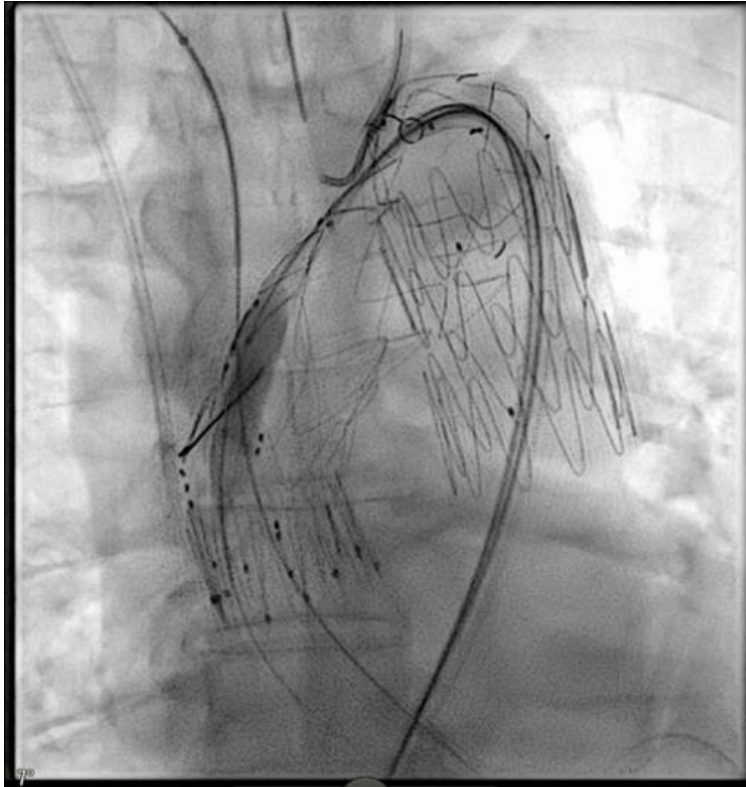Branch for left carotid artery: cannulation failure using a steerable sheath



civ
WORLD
CHALLENGES & INNOVATIONS IN VASCULAR WORLD

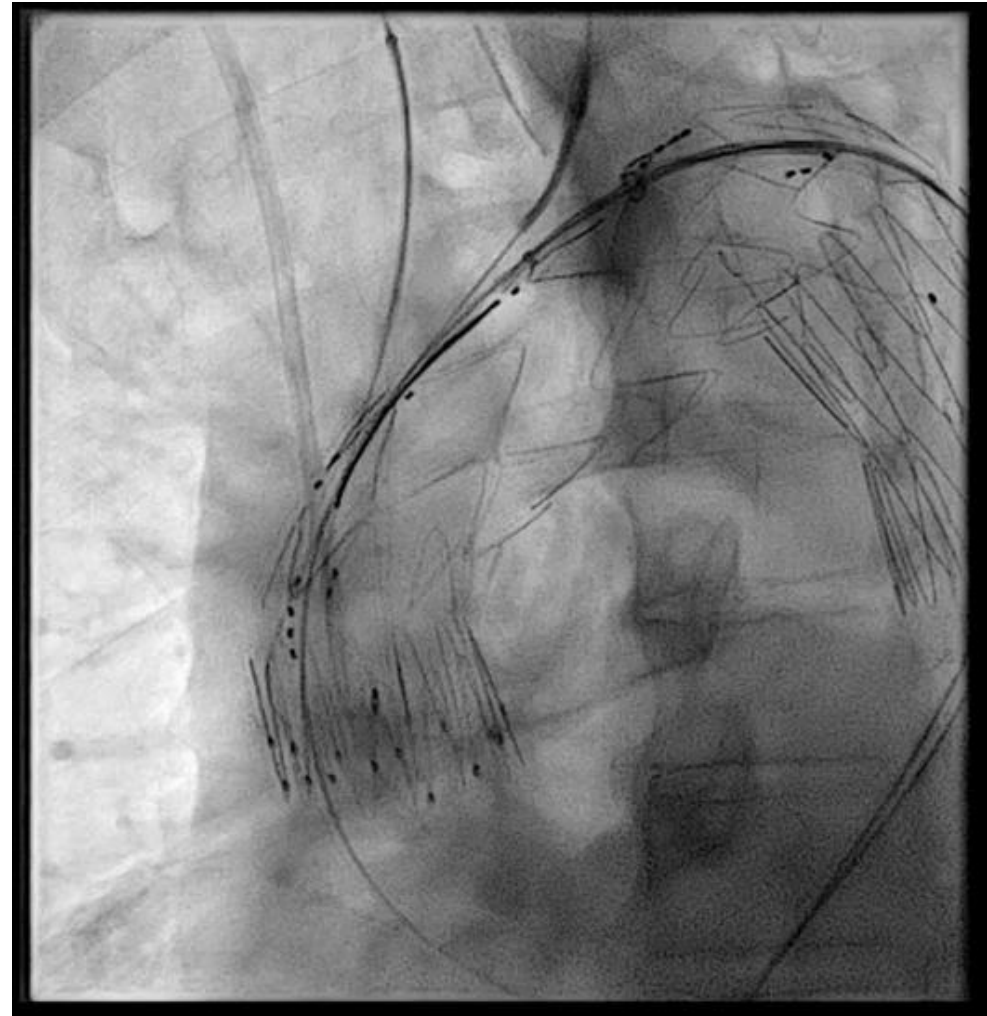
31 MARS
1^{ER} AVRIL **2026**

MÉRIDIEN ÉTOILE
PARIS



Left CCA branch access via the left SCA branch
(preloaded Catheter)

Use of over the wire Indy snare

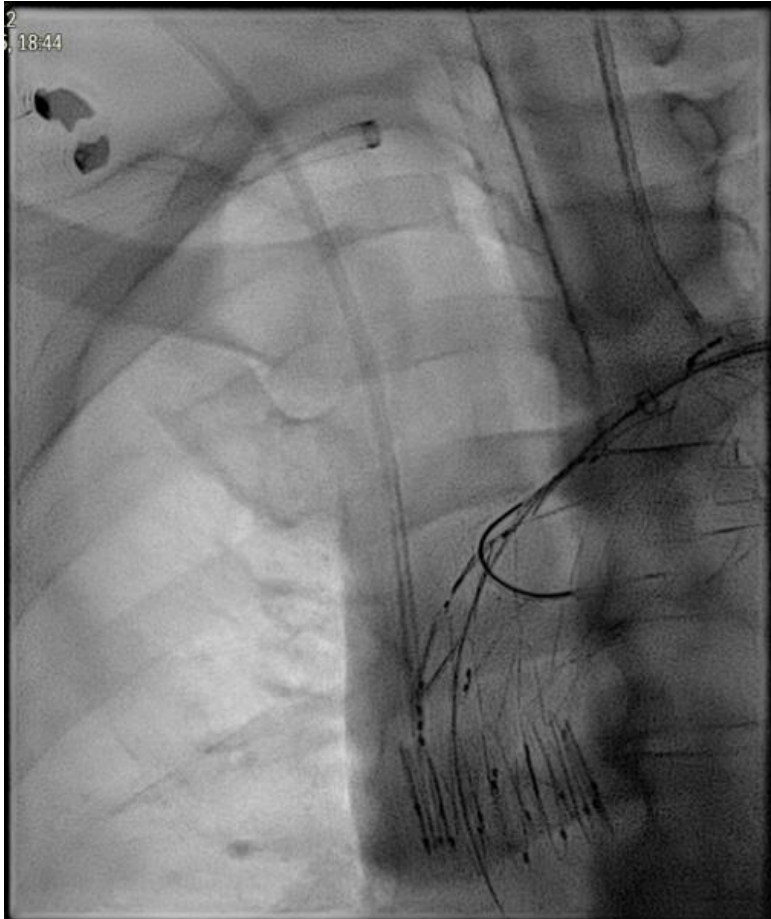





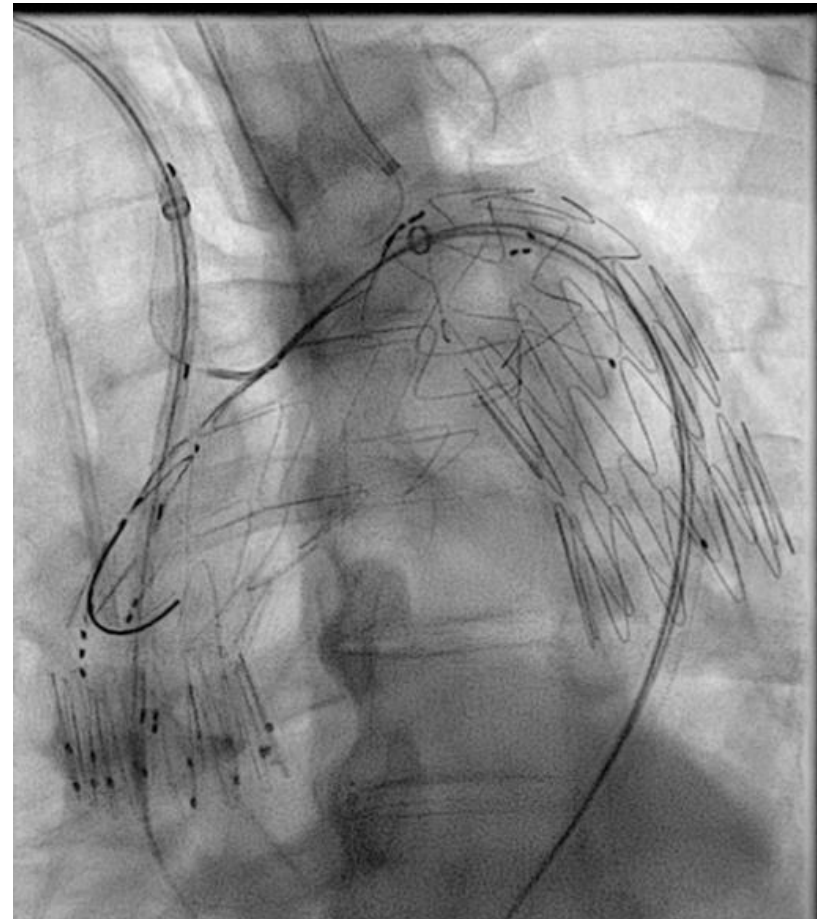
CIV
WORLD
CHALLENGES & INNOVATIONS IN VASCULAR WORLD

31 MARS
1^{ER} AVRIL **2026**

MÉRIDIEN ÉTOILE
PARIS



Loss of wire in the Innominate artery



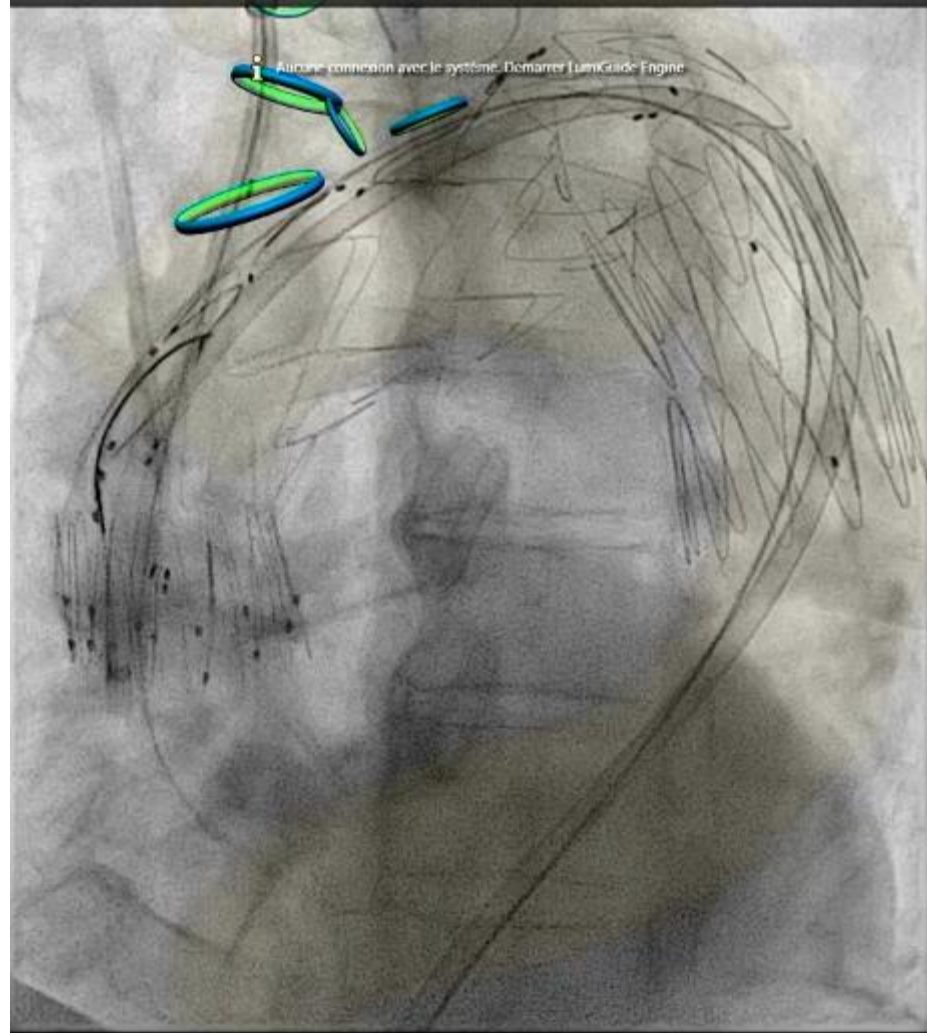

Innominate artery: Gore graft limb positioning



Cjv
WORLD
CHALLENGES & INNOVATIONS IN VASCULAR WORLD

31 MARS
1^{ER} AVRIL **2026**

MÉRIDIEN ÉTOILE
PARIS




TourGuide 8.5 F



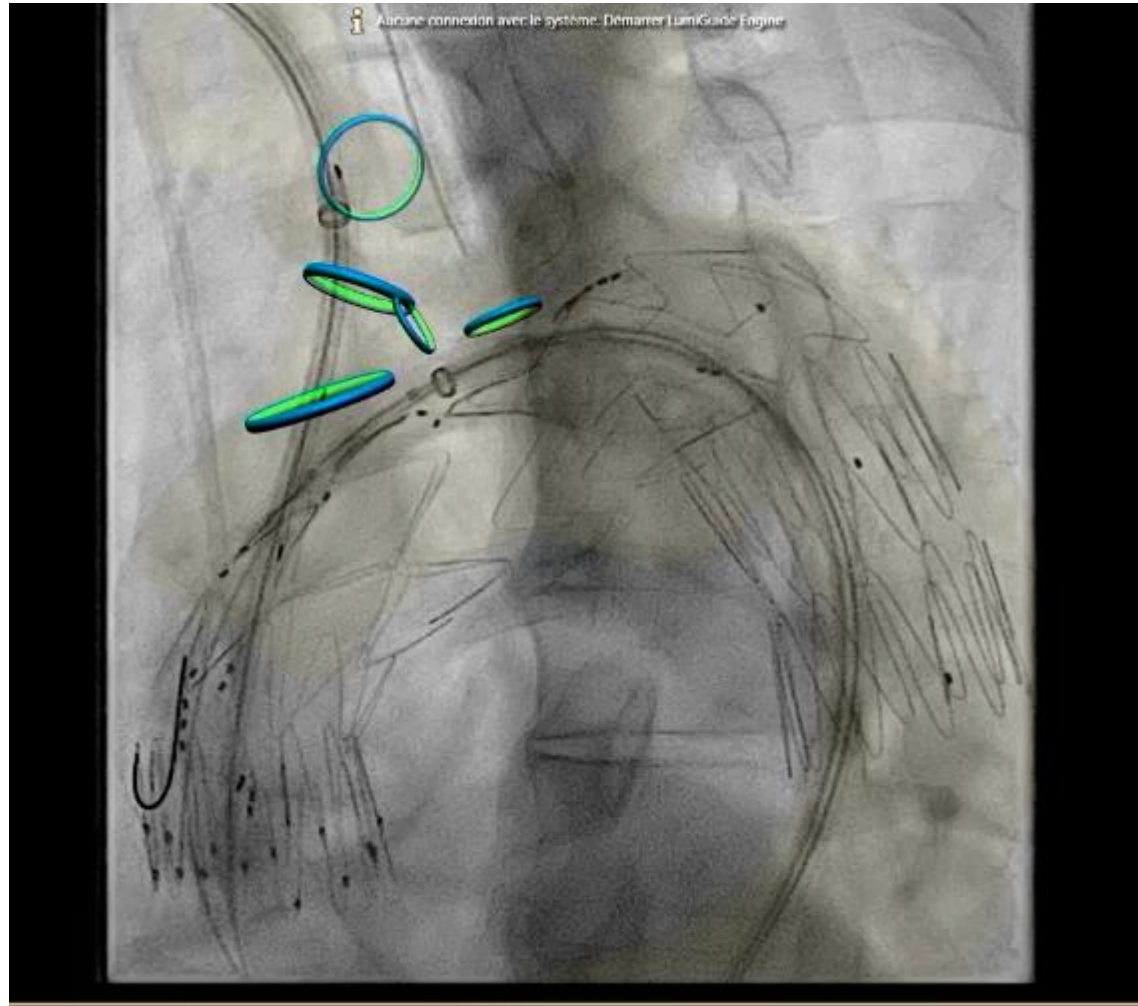
Cjv
WORLD
CHALLENGES & INNOVATIONS IN VASCULAR WORLD

31 MARS
1^{ER} AVRIL **2026**

MÉRIDIEN ÉTOILE
PARIS



19.44 pm

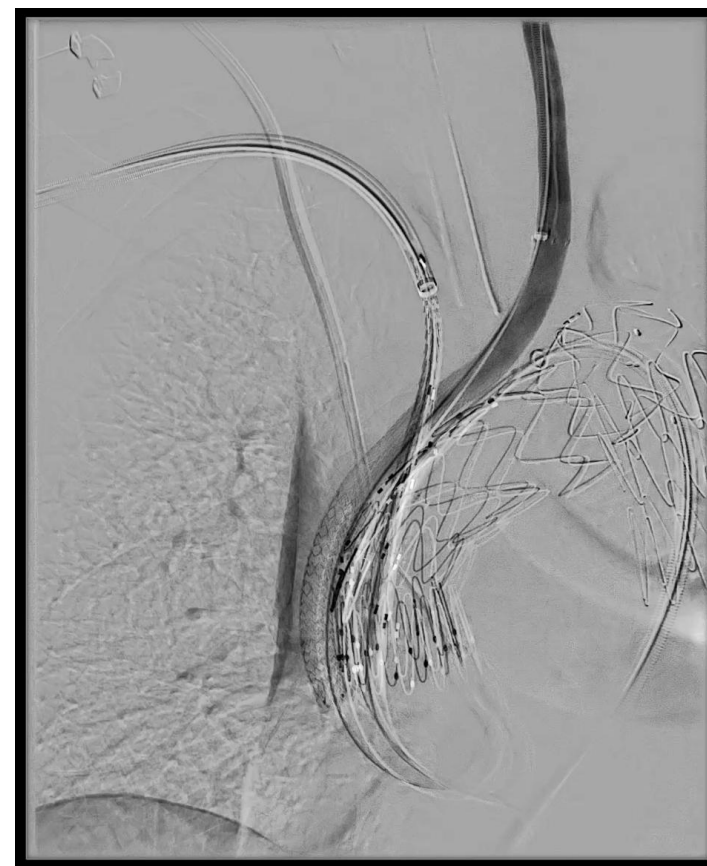
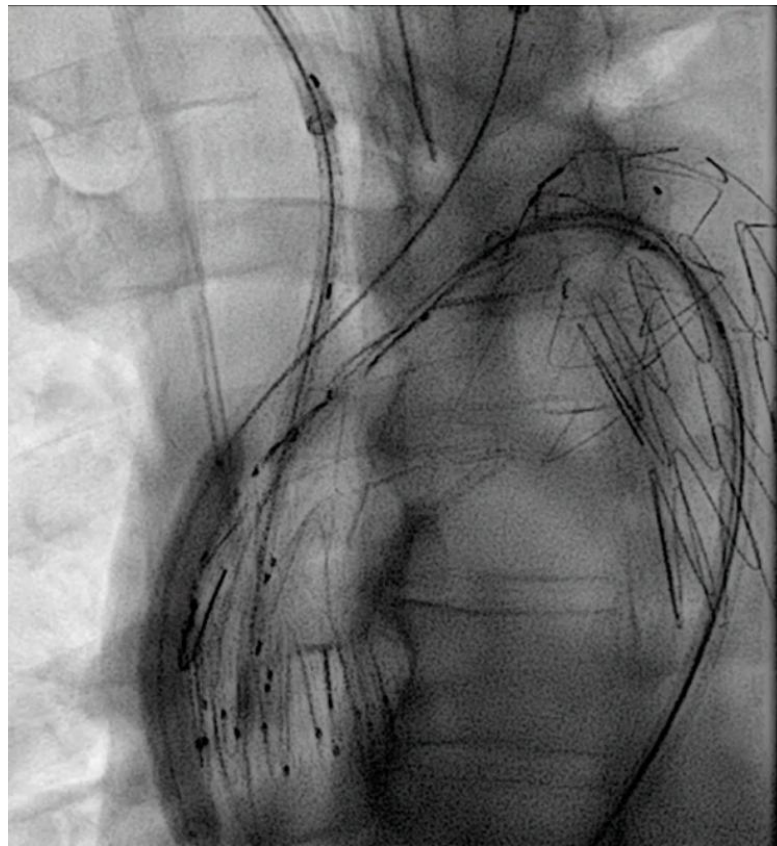
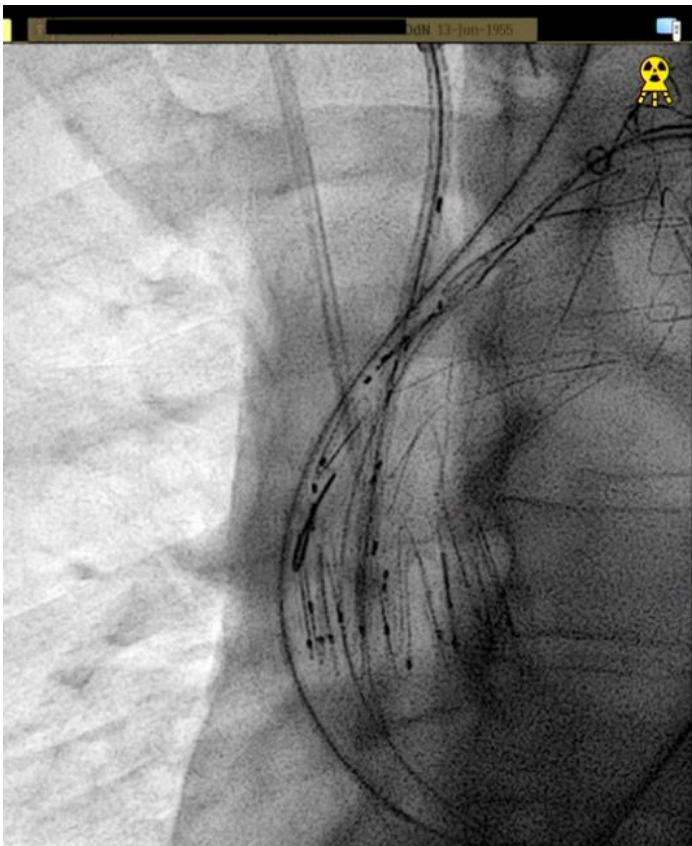




CIVA
WORLD
CHALLENGES & INNOVATIONS IN VASCULAR WORLD

31 MARS
1^{ER} AVRIL **2026**

MÉRIDIEN ÉTOILE
PARIS



20.08

K total: 1106 mGray

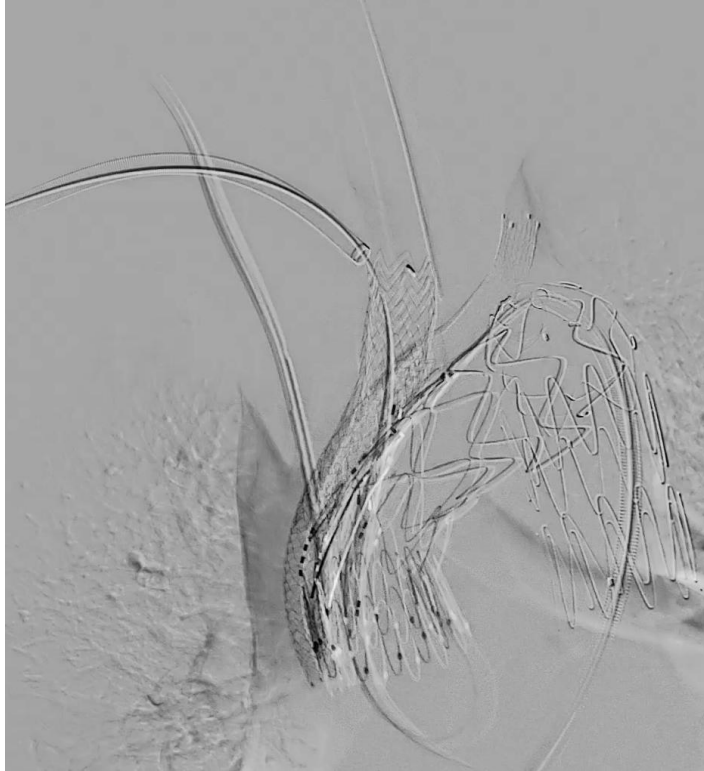

Chimney for the left common carotid artery



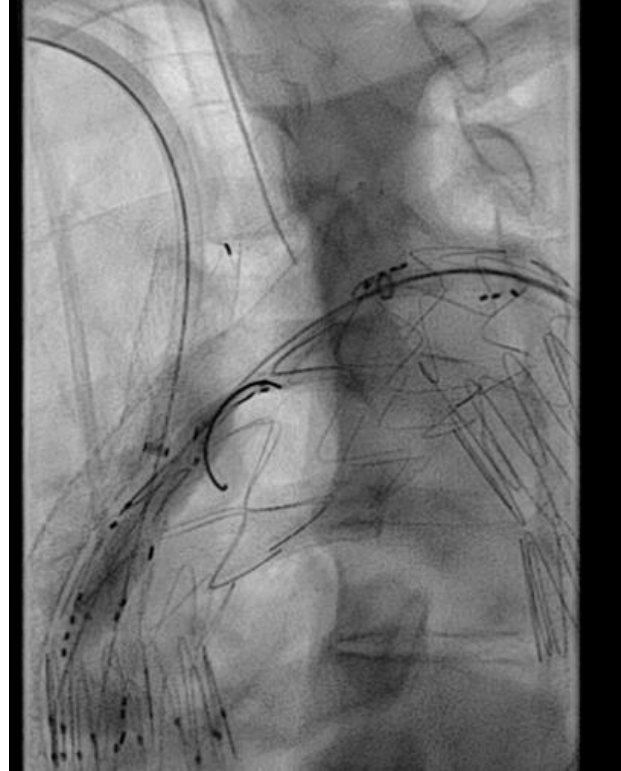
Cjv
WORLD
CHALLENGES & INNOVATIONS IN VASCULAR WORLD

31 MARS
1^{ER} AVRIL **2026**

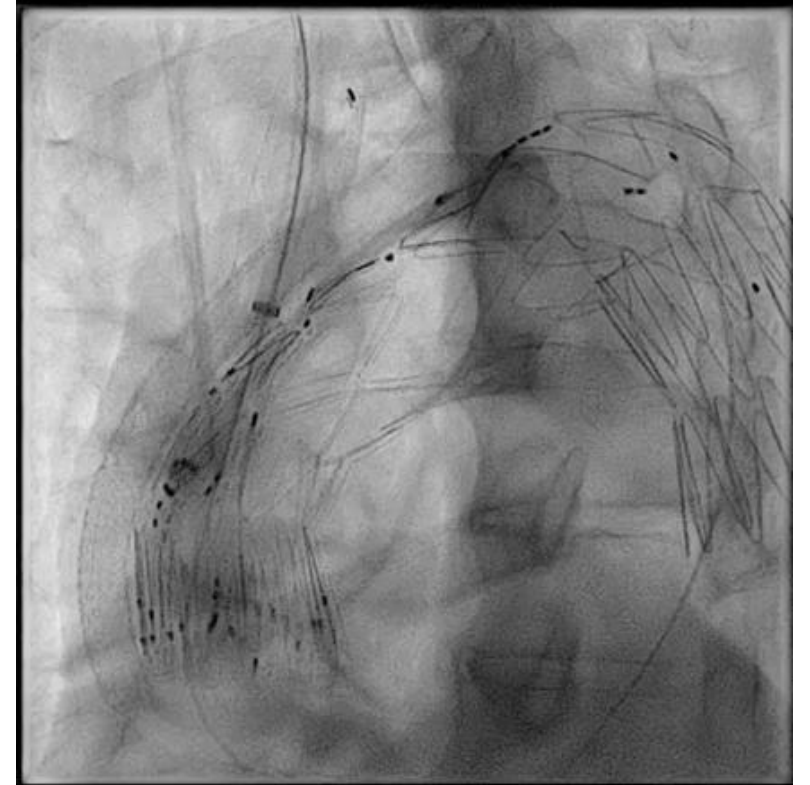MÉRIDIEN ÉTOILE
PARIS



Deployment of Innominate artery
bridging limb



Advanta covered stent
32mm
In the left CCA branch



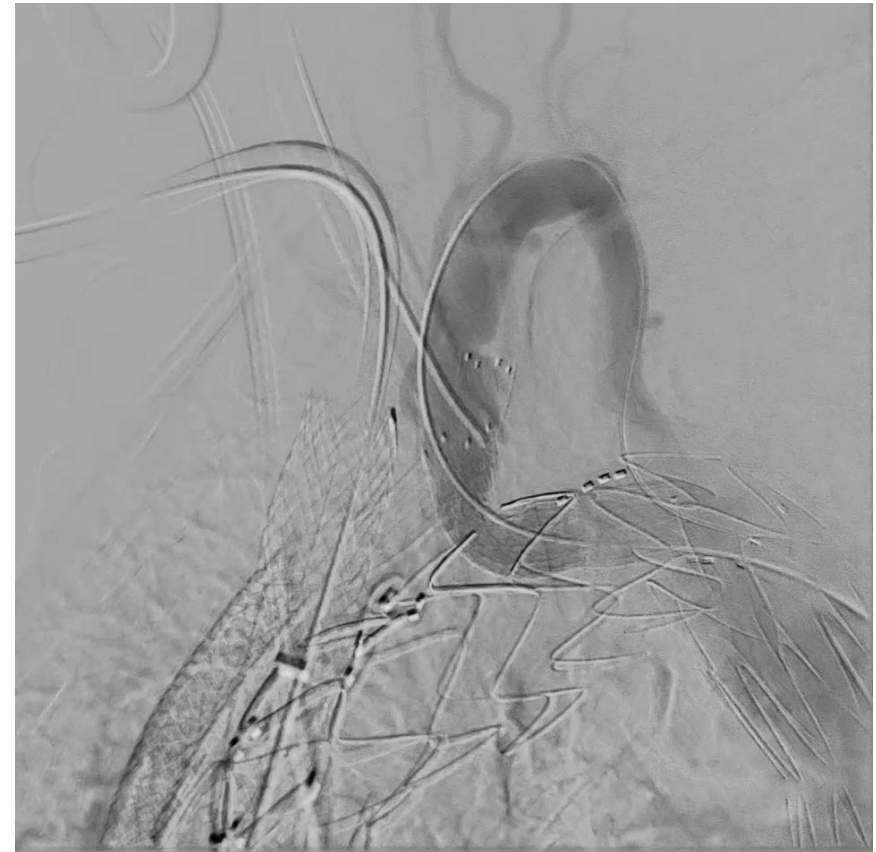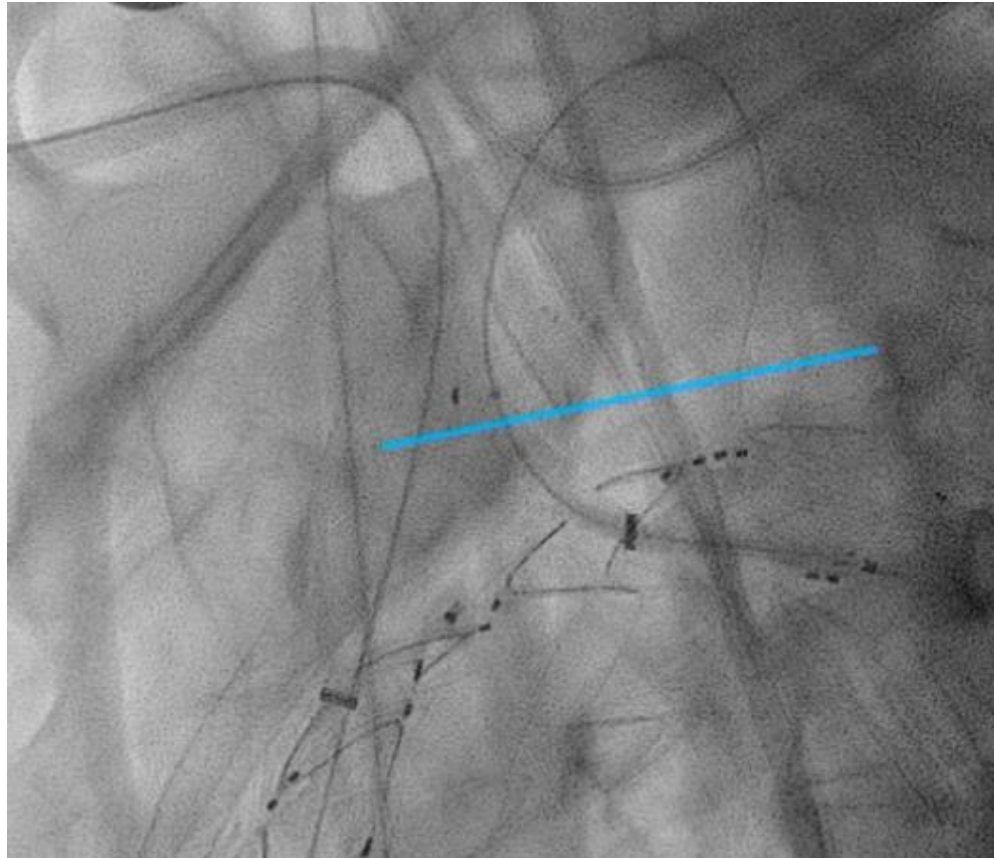

Left CCA branch occlusion with an
Amplatzer device.



civ
WORLD
CHALLENGES & INNOVATIONS IN VASCULAR WORLD

31 MARS
1^{ER} AVRIL **2026**

MÉRIDIEN ÉTOILE
PARIS



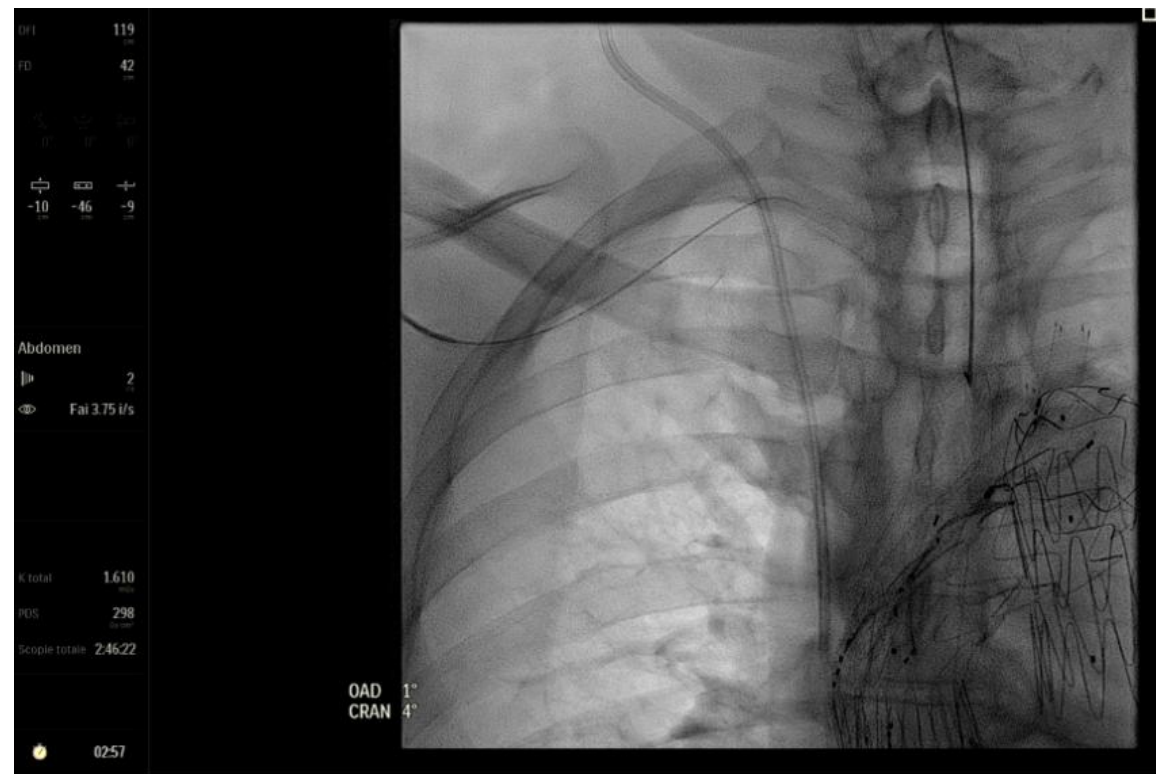
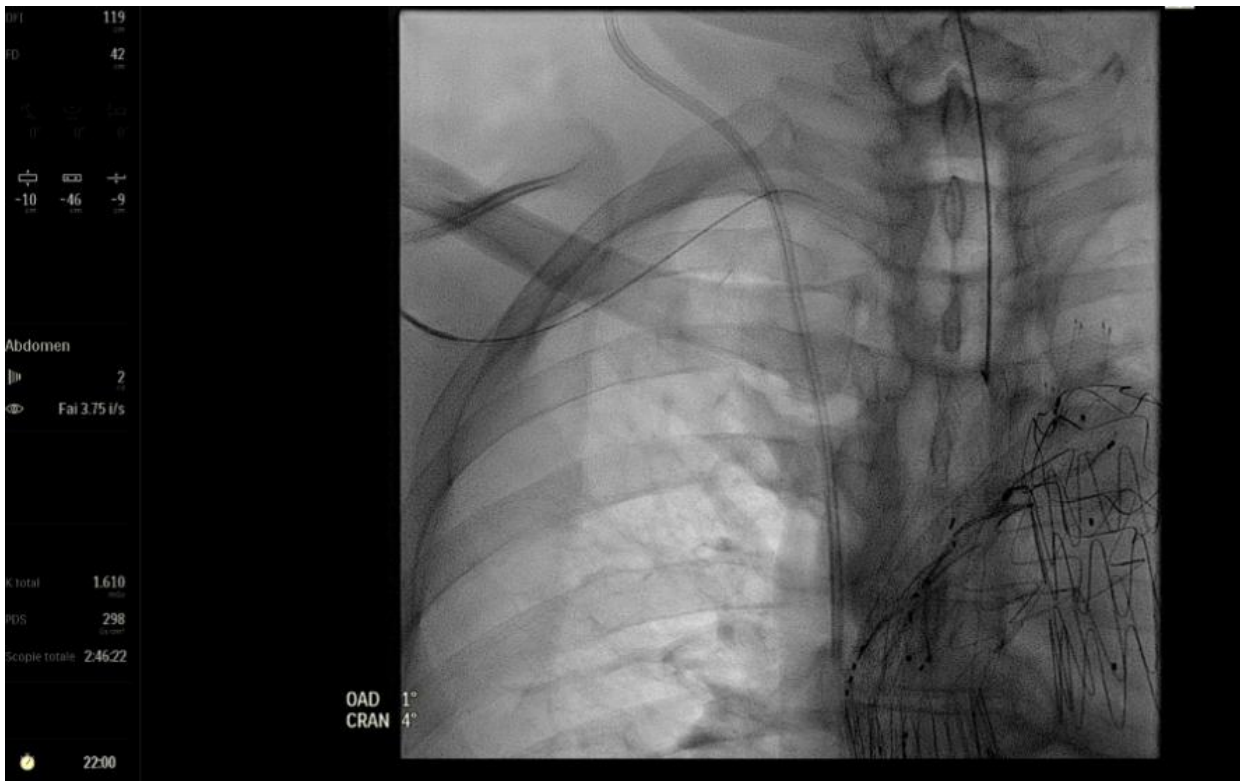
Bridging stent for the left SCA



CIV
WORLD
CHALLENGES & INNOVATIONS IN VASCULAR WORLD

31 MARS
1^{ER} AVRIL **2026**

MÉRIDIEN ÉTOILE
PARIS




22.00

2.57



CIV
WORLD
CHALLENGES & INNOVATIONS IN VASCULAR WORLD

31 MARS
1^{ER} AVRIL **2026**
MÉRIDIEN ÉTOILE
PARIS



22.00



gifbin.com



Cjv
WORLD
CHALLENGES & INNOVATIONS IN VASCULAR WORLD

31 MARS
1^{ER} AVRIL **2026**
MÉRIDIEN ÉTOILE
PARIS



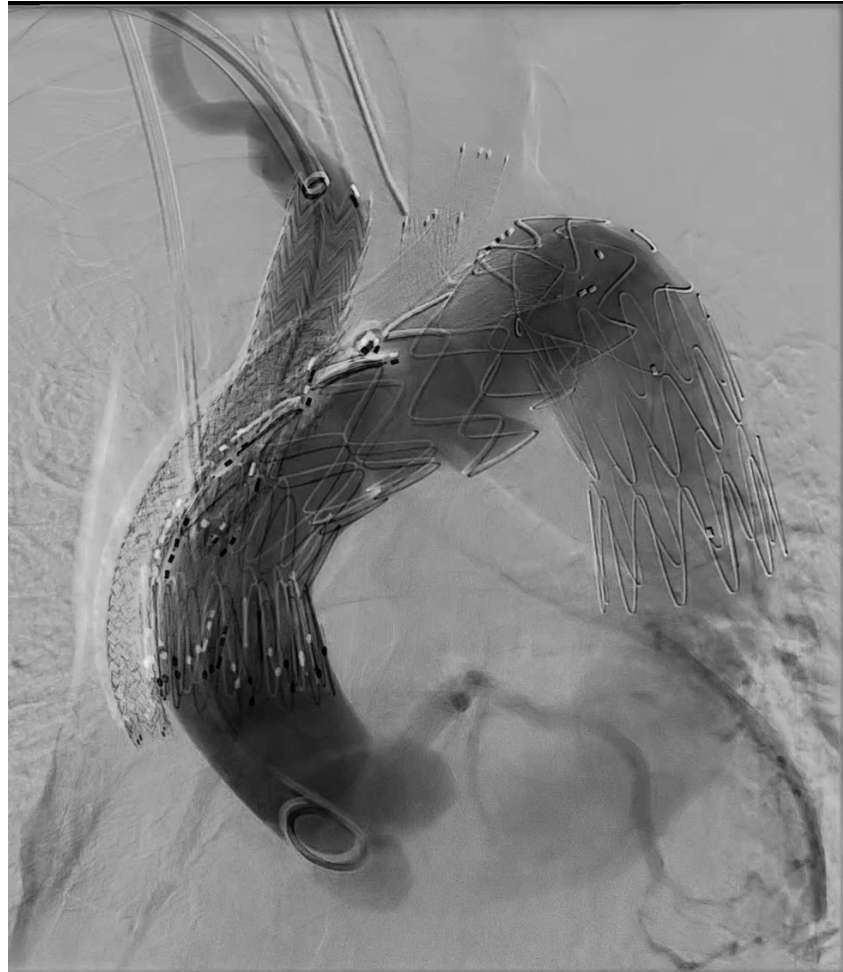
Unsuccessful percutaneous closure of the femoral artery

Manual compression of the groin



CIV
WORLD
CHALLENGES & INNOVATIONS IN VASCULAR WORLD

31 MARS
1^{ER} AVRIL **2026**
MÉRIDIEN ÉTOILE
PARIS



But...


excellent pulse of the left common carotid artery



Cjv
WORLD
CHALLENGES & INNOVATIONS IN VASCULAR WORLD

31 MARS
1^{ER} AVRIL **2026**

MÉRIDIEN ÉTOILE
PARIS



« Alors, qu'est ce qui s'est passé... »

« Tu sais, dans ce cas, je réfléchis toujours conformément à mon expérience d'expert auprès des tribunaux »

« Je lui ferais un pontage croisé carotido carotidien... après la fermeture du Scarpa »


« mais si tu es fatigué je peux venir le faire »



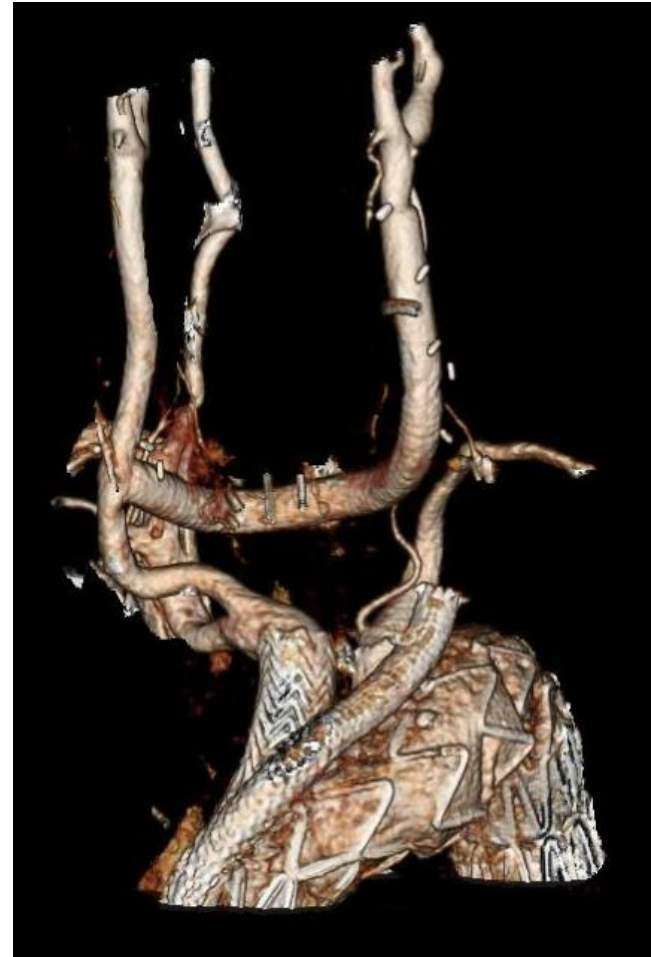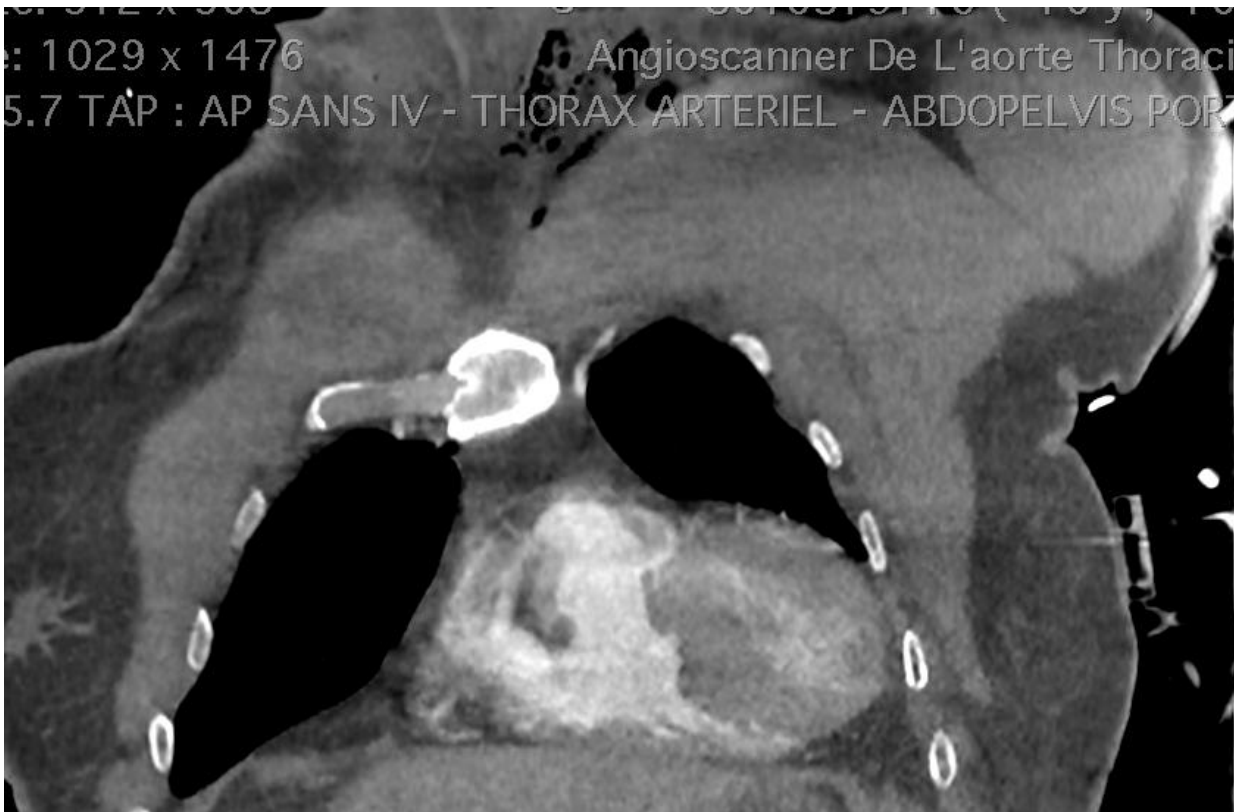Cjv
WORLD
CHALLENGES & INNOVATIONS IN VASCULAR WORLD


31 MARS
1^{ER} AVRIL **2026**

MÉRIDIEN ÉTOILE
PARIS



Uneventful post op outcome...!





ciw

WORLD

CHALLENGES & INNOVATIONS IN VASCULAR WORLD

31 MARS **2026**
1^{ER} AVRIL

MÉRIDIEN ÉTOILE
PARIS
