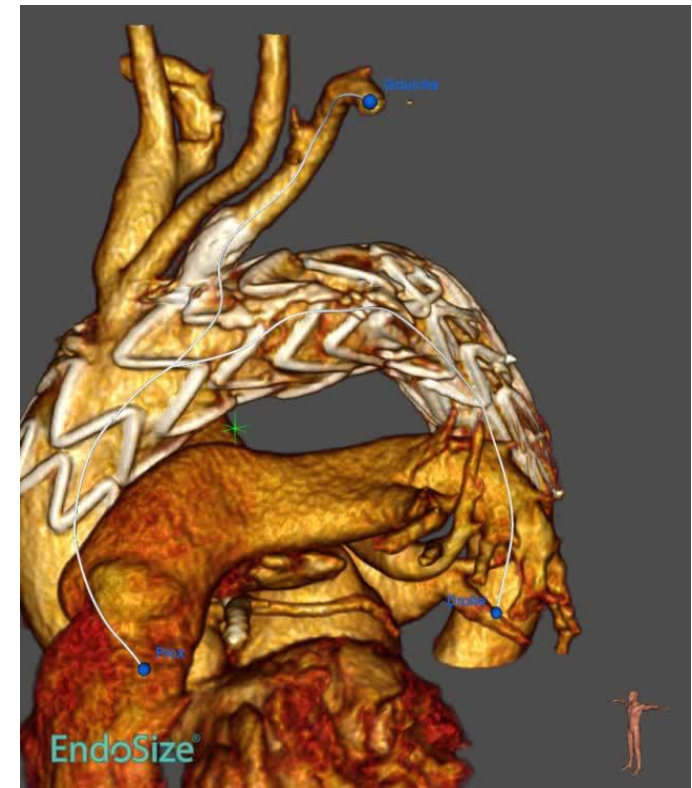

# Endovascular treatment of the aortic arch: the brachiocephalic trunk and the left carotid artery should remain “no-stenting” zones.

Pr L Canaud

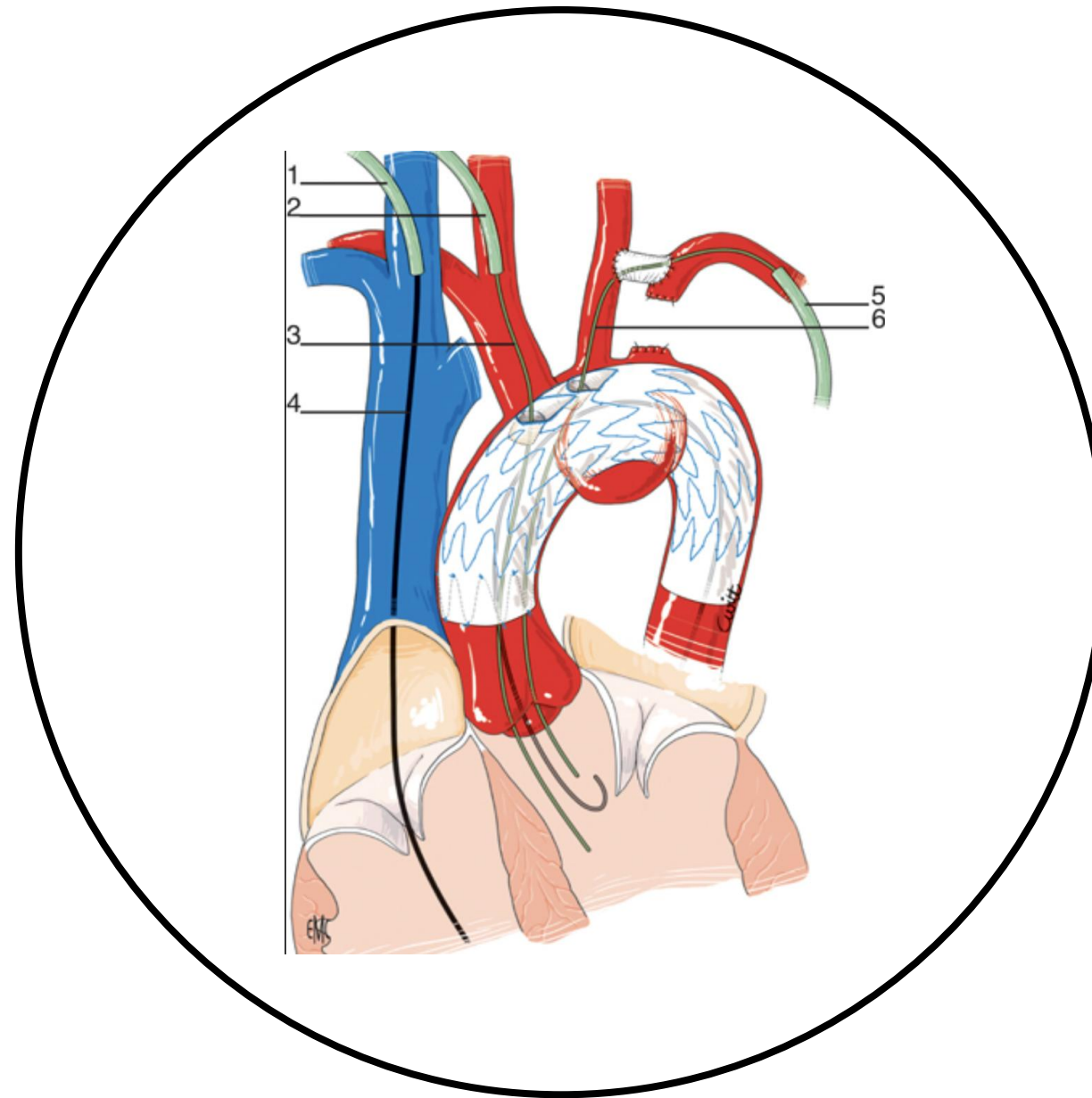
Pr T Gandet

Montpellier, France



# **Current options for endovascular repair of the arch**

# Custom-made: total endovascular repair



# Custom-made: total endovascular repair

**Since 2007: 273 cases**  
**Less than 20 cases per year worldwide**

## Results

- All-cause mortality was 16% (95% CI 8%-26%)
- Stroke 14% (8%-24%)
- Endoleaks were identified in 13% (7%-25%)

## A Systematic Review of Total Endovascular Aortic Arch Repair: A Promising Technology

[Ameen M Basha](#)<sup>1</sup>, [Randy D Moore](#)<sup>2</sup>, [Kenton L Rommens](#)<sup>2</sup>, [Eric J Herget](#)<sup>3</sup>, [R Scott McClure](#)<sup>4</sup>

Affiliations + expand



# Rational 4: No endovascular grafts in the carotid arteries

- 30 day stroke rate: 5%
- 1 year stroke rate: 23%
- Thrombus formation: 7/27: 26%

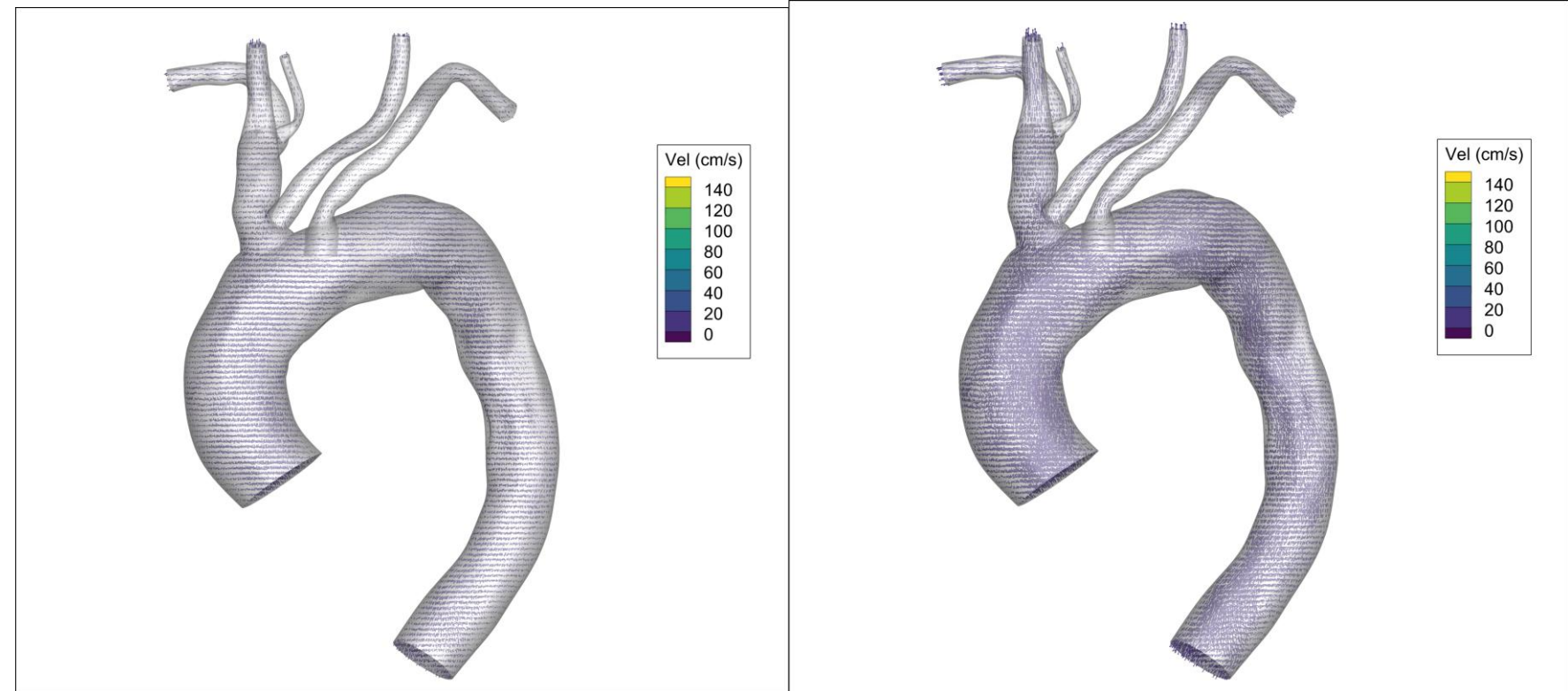
European Journal of Vascular and  
Endovascular Surgery

Available online 23 July 2024

In Press, Journal Pre-proof [? What's this?](#)

Branch Thrombus after  
Endovascular Treatment  
with Arch Branched  
Devices for Aortic Arch  
Pathologies

Charlotte C. Lemmens <sup>a</sup>  , Tom J.A.J. Konings <sup>a</sup>,  
Anastasia Dean <sup>b</sup>, Anders Wanhainen <sup>b c</sup>,  
Kevin Mani <sup>b</sup>, Sinead Gormley <sup>d</sup>, Manar Khashram <sup>d</sup>,  
Barend M.E. Mees <sup>a</sup>, Geert Willem H. Schurink <sup>a</sup>



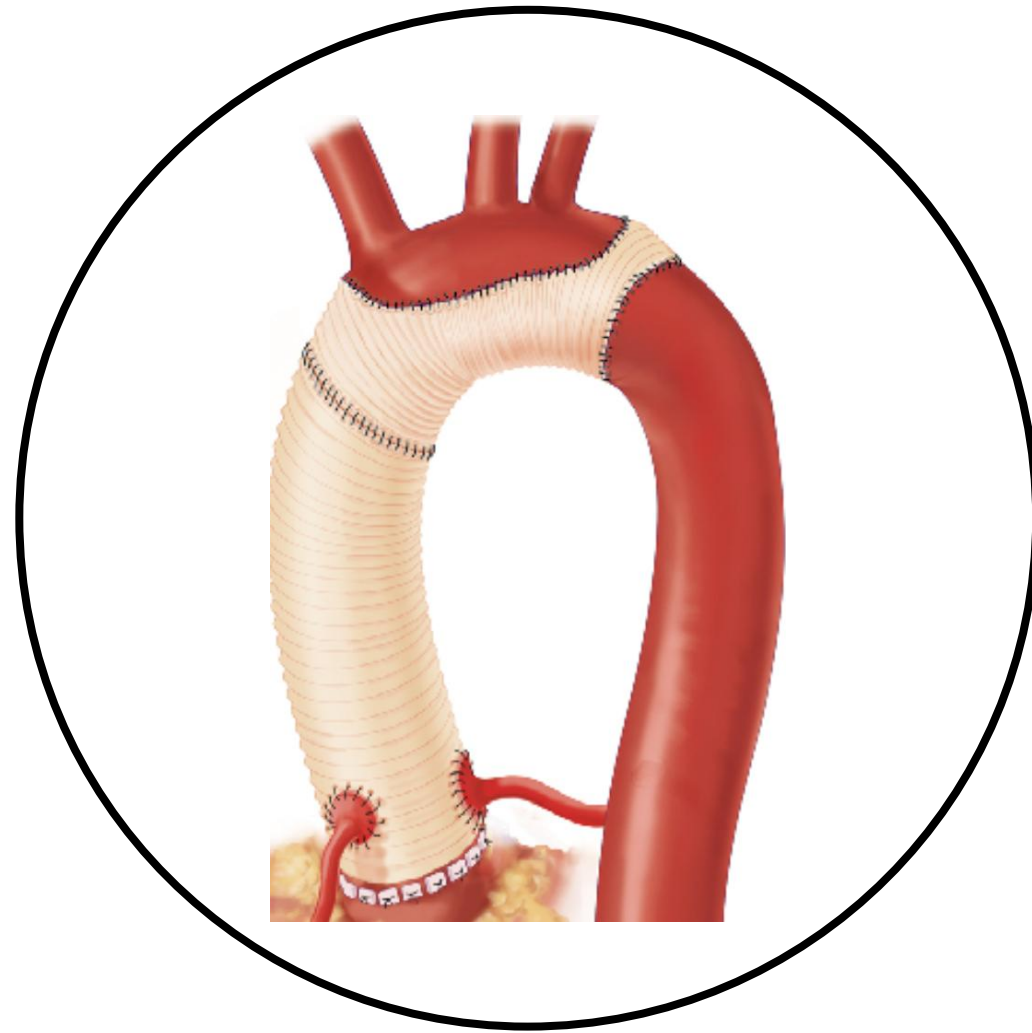
**Before Stent Graft  
implant**

**After Stent Graft  
implant**

**How to decrease stroke rate during total endovascular repair of the aortic arch?**

# Total arch repair

How open surgery inspired the homemade double fenestrated design

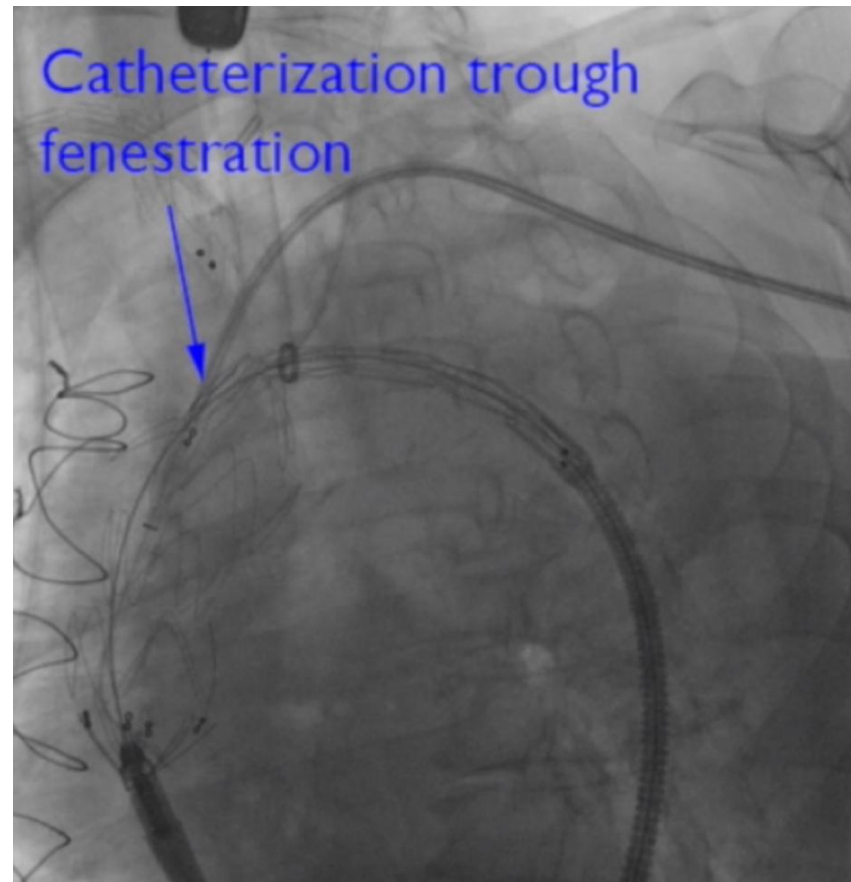


**To avoid carotid manipulations**  
**To decrease aortic arch manipulations**



# Total arch repair without carotid manipulations

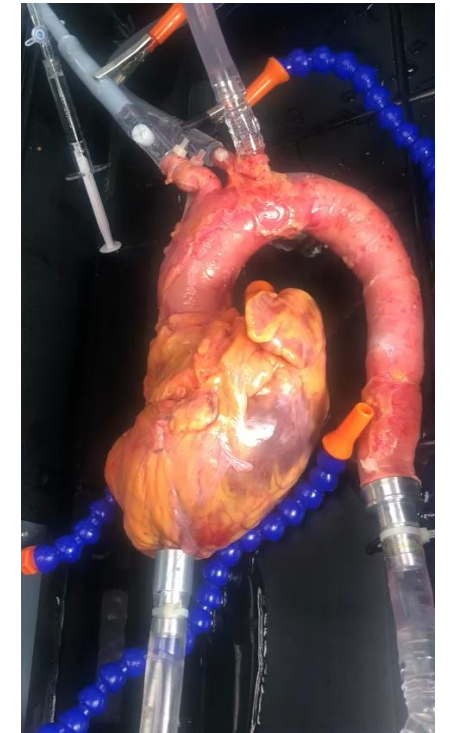
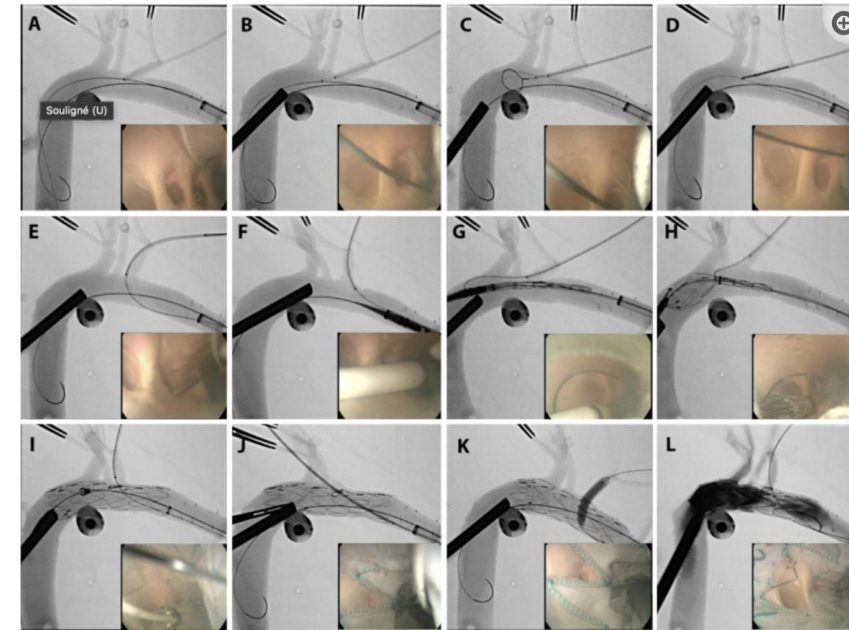
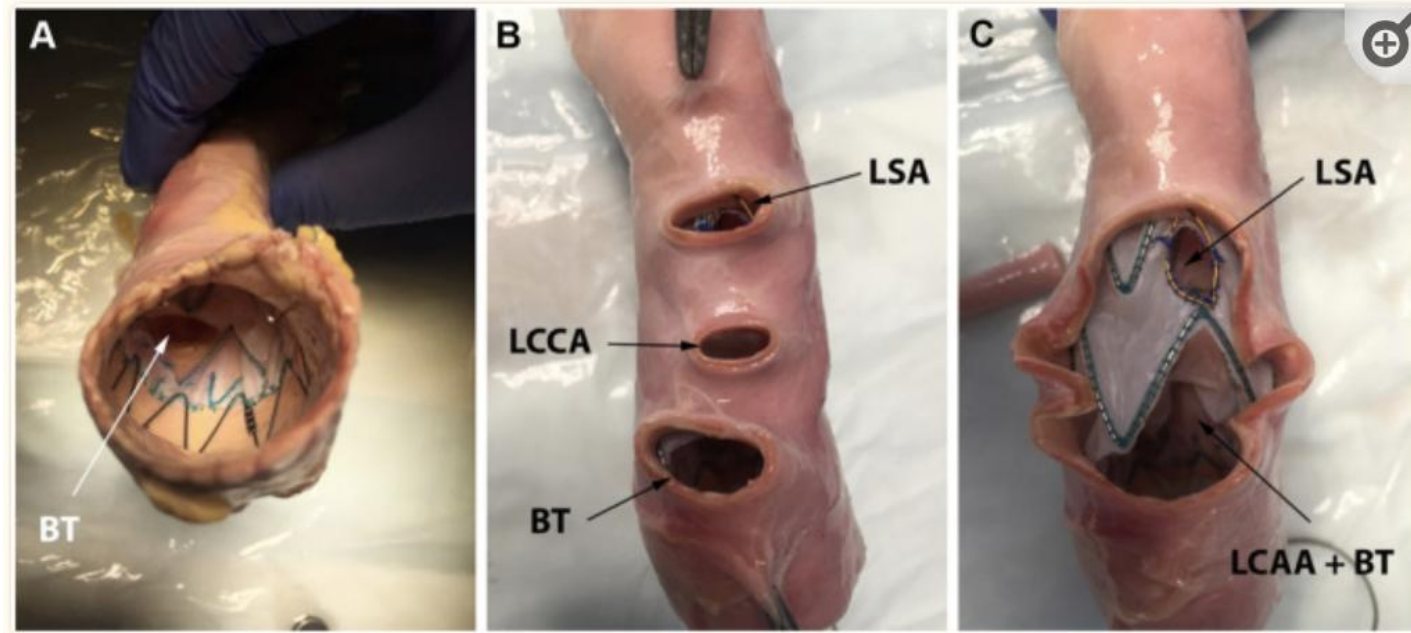
- With the proximal fenestrations being directed to the orifices of the BT and LCCA automatically
- When LSA fenestration is catheterized and secured by covered stent placement



**To avoid carotid manipulations**  
**To decrease aortic arch manipulations**



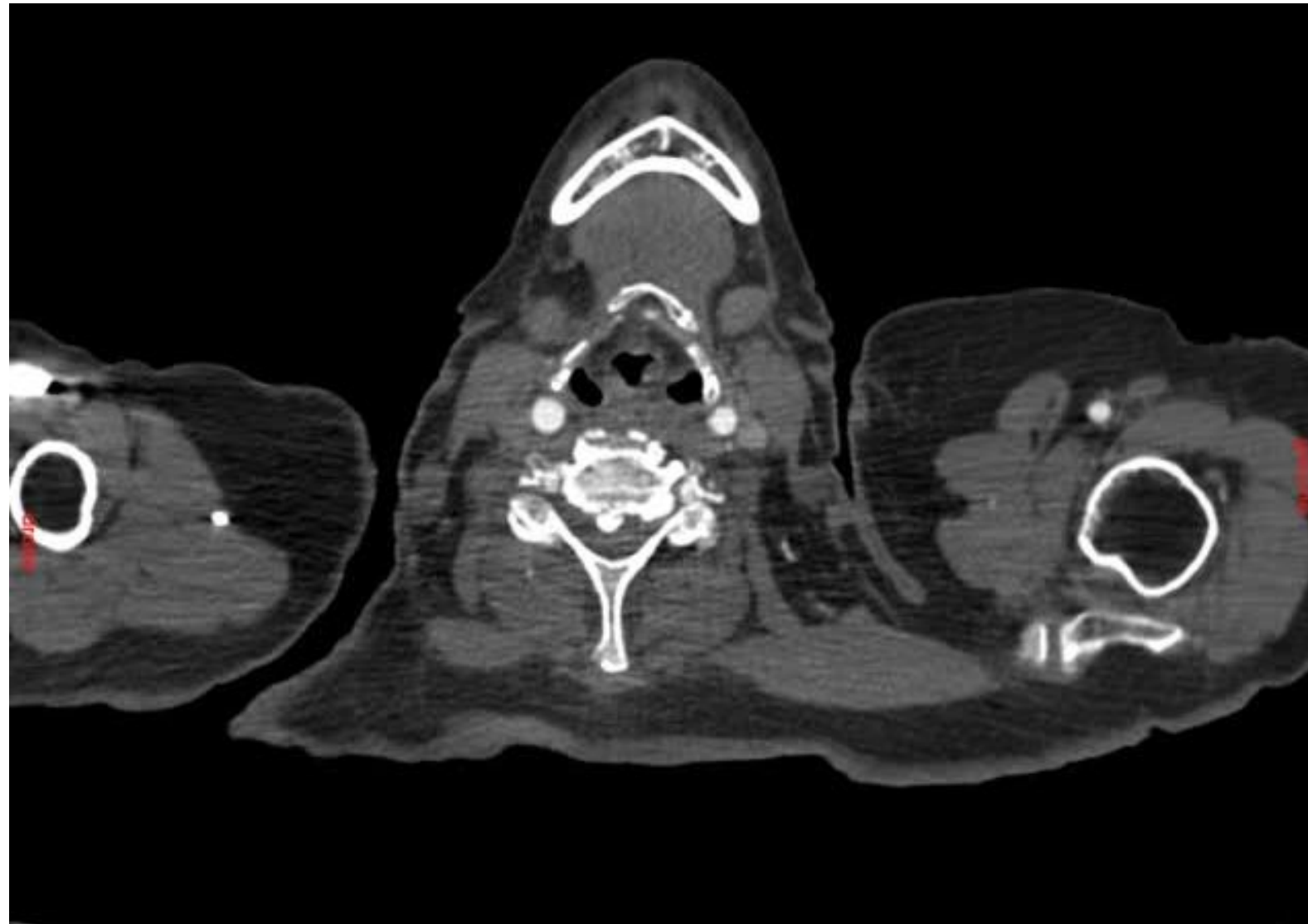
# Experimental evaluation



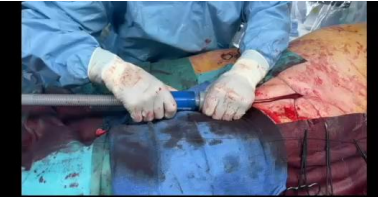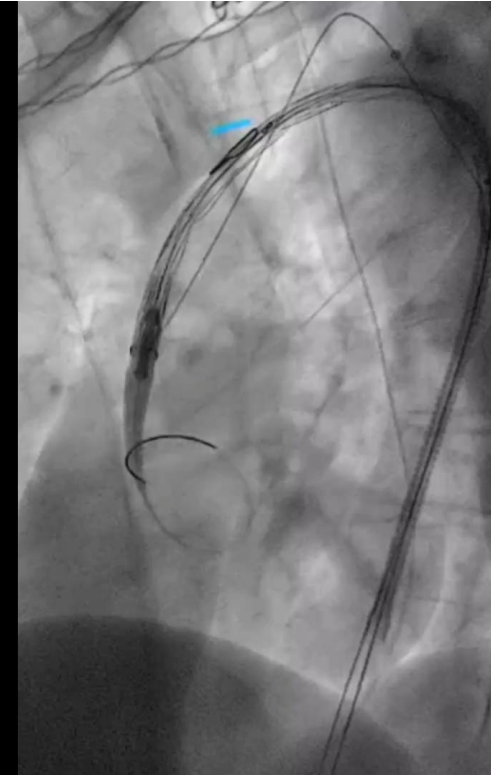*Lounes, Canaud L et al. Endovascular aortic arch repair with a pre-cannulated double-fenestrated physician-modified stent graft: a benchtop experiment*

*Intercativ CardiovascThorac 2022.*

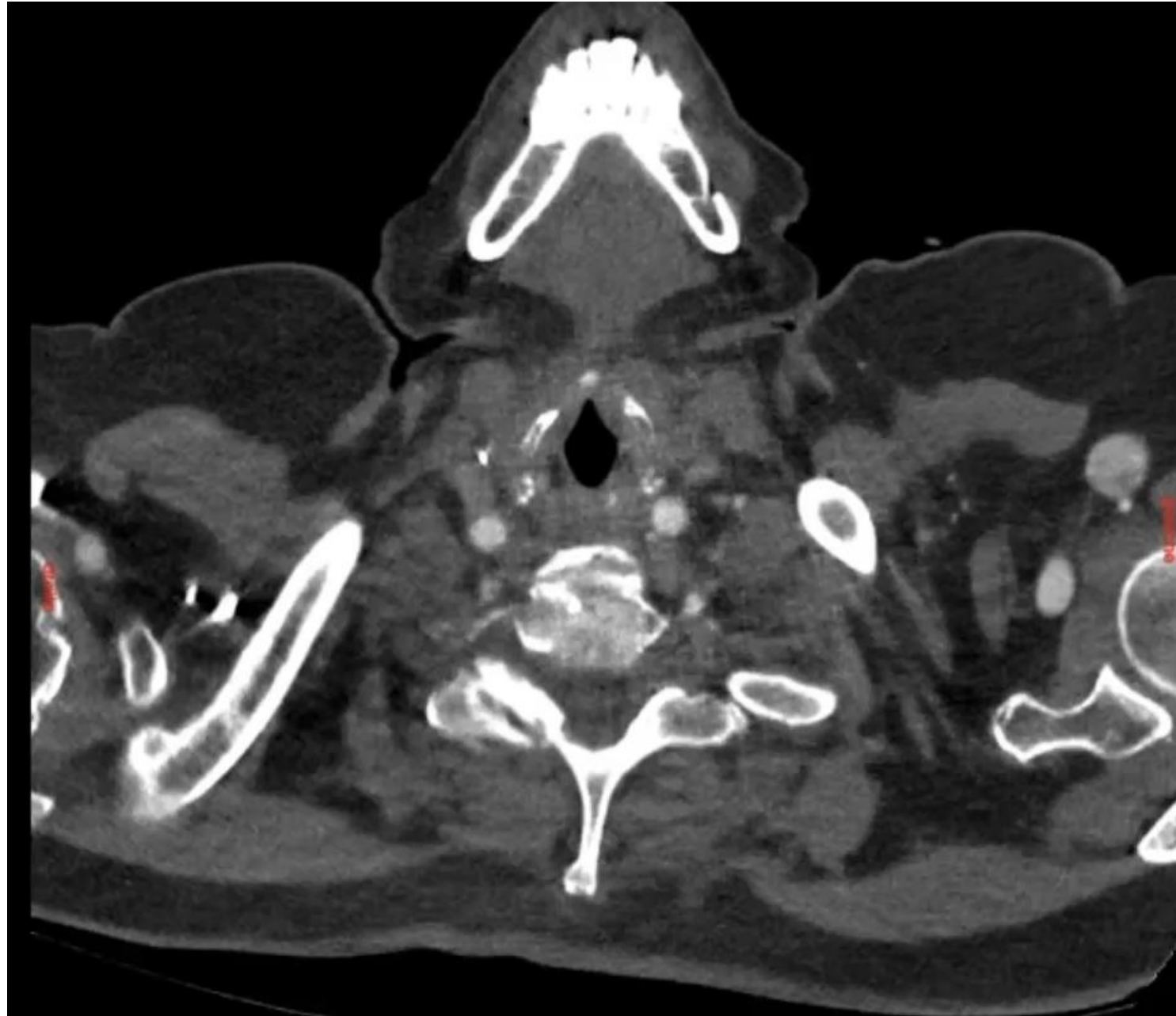## Residual type A aortic dissection



**DEPLOYMENT OF A STANDARD FOUBLE FENESTRATED TEVAR**

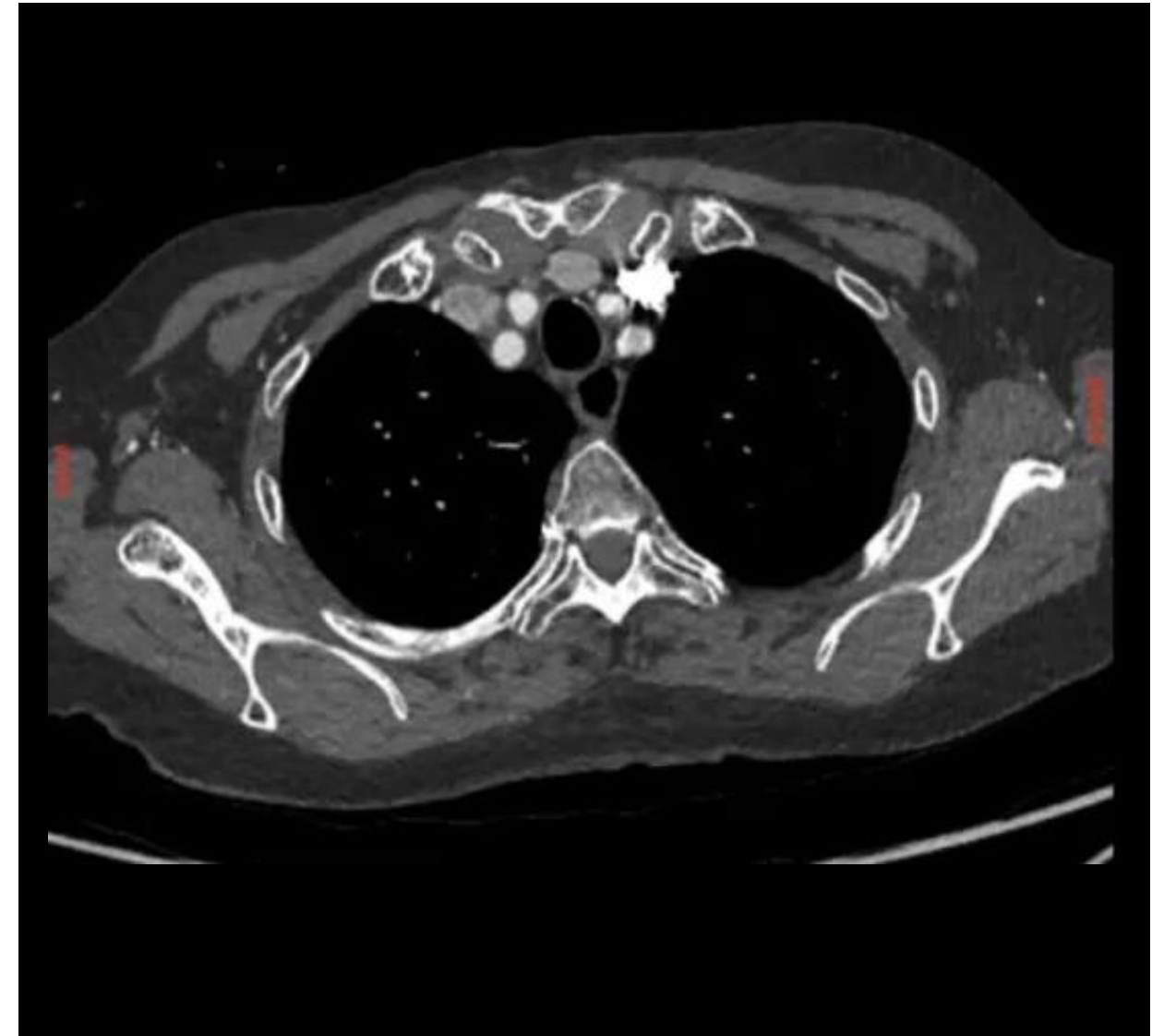


## Residual type A aortic dissection



# Total arch repair

- Out of the 310 fenestrated TEVAR for the aortic arch
- **308 cases:** June 2017 February 2025
- Double fenestration:
- **Elective: 78.1%** (n=240)
- Indications:
  - Degenerative aneurysm
  - Dissecting aortic arch aneurysms subsequent to surgical treatment of acute type A dissections
  - Chronic complicated type B aortic dissection
  - Acute complicated type B aortic dissection



*Canaud L. JVS 2018. JVS 2020. JEVT 2022*

*Double homemade fenestrated stent graft for total endovascular aortic arch repair.*

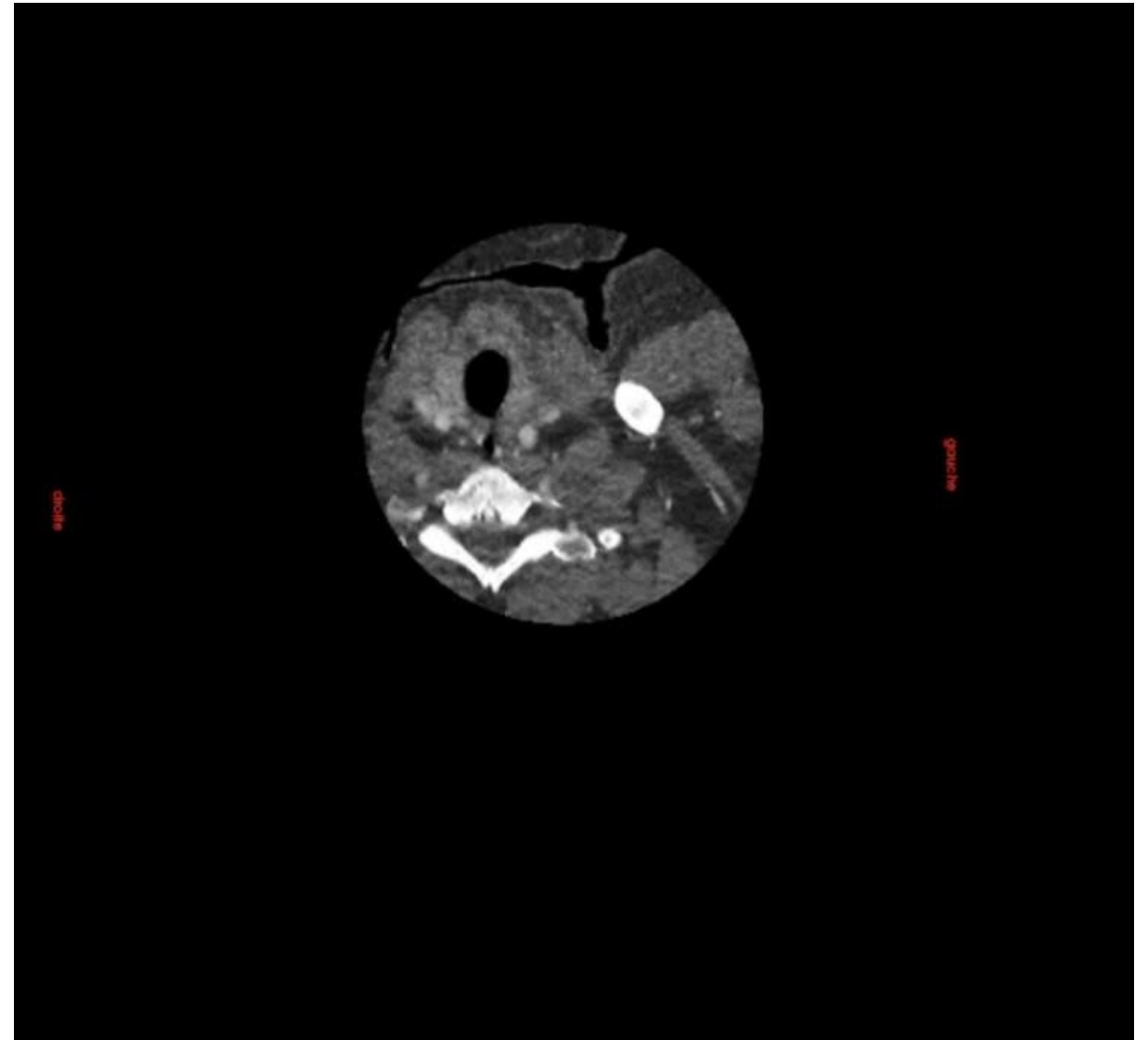
# Total arch repair

- Stent graft modification: **19 minutes** (range 16-20)
- **Endovascular exclusion: 100%**
- One failed deployment: Chimney procedure
- Additional planned endovascular procedure: 10
  - Closure of supra-aortic trunks re-entry tears
  - One transcatheter aortic valve replacement for severe native aortic valve regurgitation.

PATIENT 1  
ZONE 1  
DEGENERATIVE AORTIC ARCH ANEURYSM  
( 9CMS )

# Total arch repair

- 4 patient had a **stroke (1.7%)** and 2 permanent sequelae:
- Overall **mortality was 1.7%**:
  - Iliac rupture: 2
  - RTAD: 2
- All left supra-aortic trunks were patent
- One type I endoleak
- 5 retrograde type A aortic dissection
- During a mean follow up of  $34 \pm 2$  months, there were no conversions to open surgical repair, aortic rupture, paraplegia



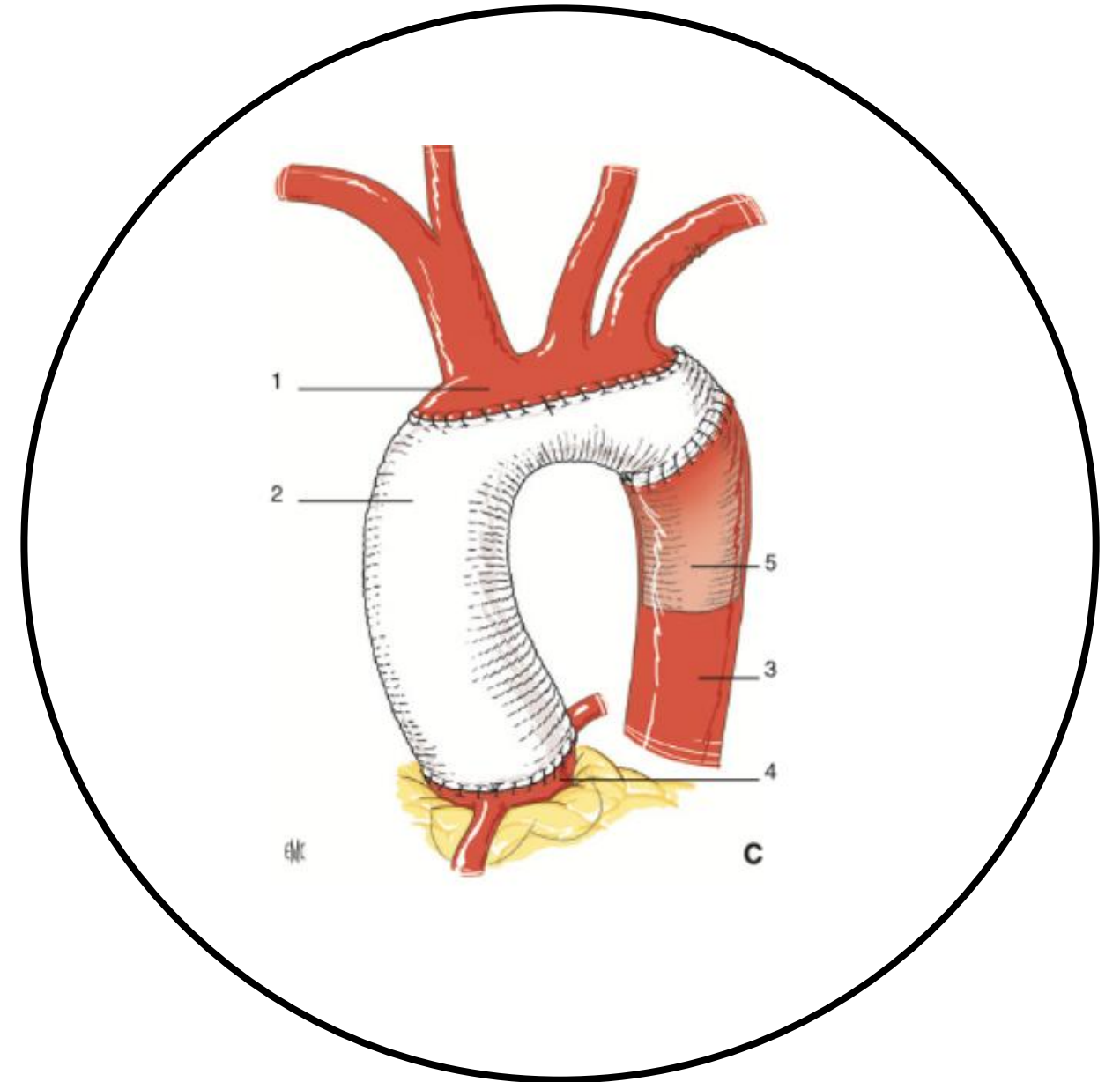
*Canaud L. JVS 2018. JVS 2020. JEVT 2022*

*Double homemade fenestrated stent graft for total endovascular aortic arch repair.*

# Discussion

## Rational 1: outer part of the aortic arch is often spared by aortic disease

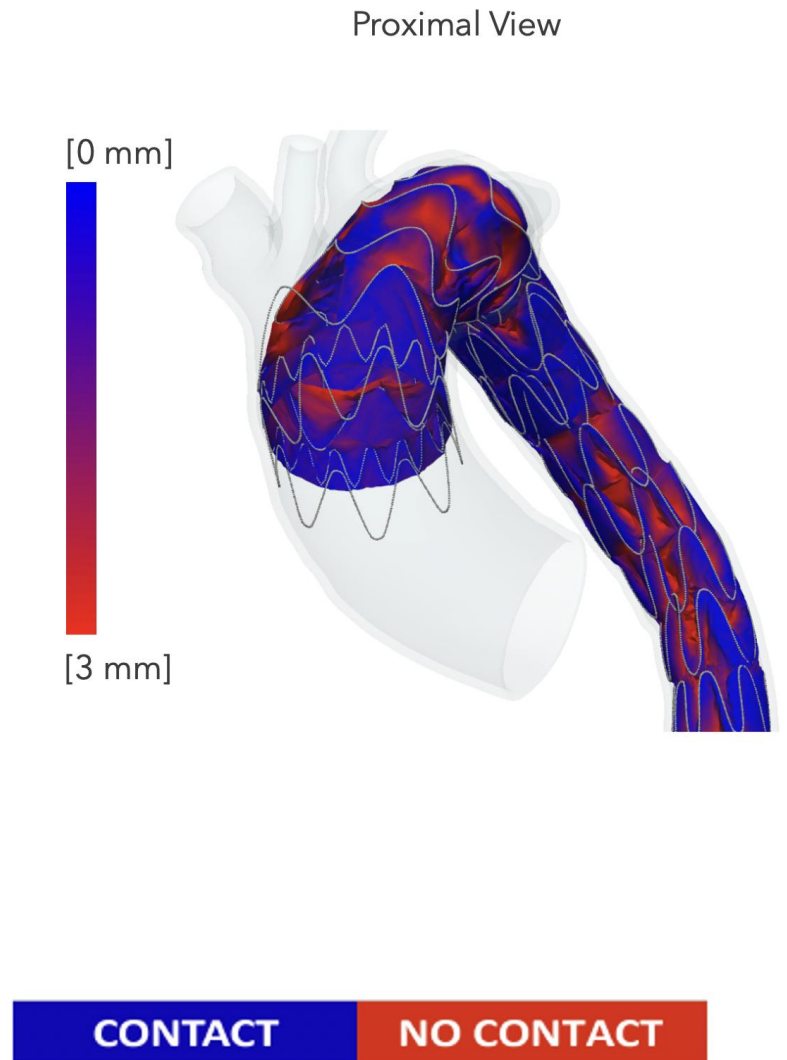
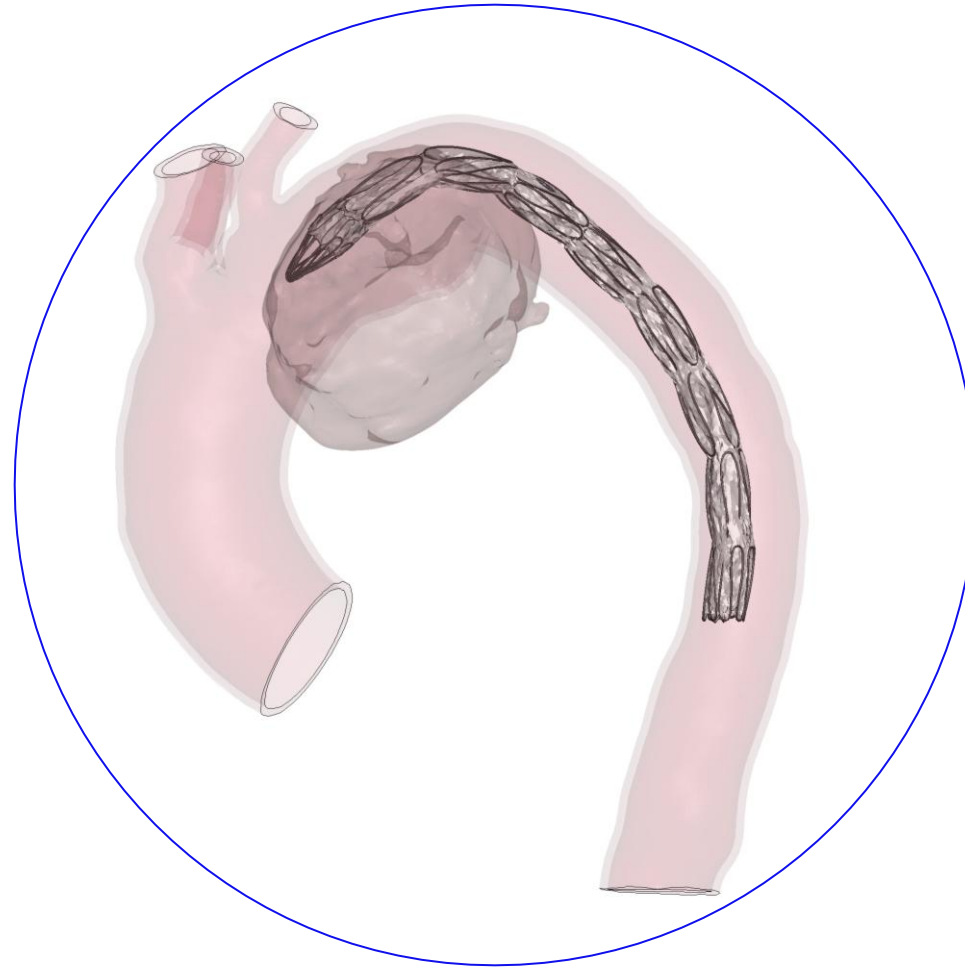
- Most often, the **outer part of the aortic arch**, from which the supra-aortic trunks originate, is **spared by aortic disease**.
- **Island technic** was the **gold standard** and is still equivalent vs trifurcated branched surgical graft



Is a four-branched prosthesis advantageous over a straight prosthesis in Frozen elephant trunk surgery? Smith T, Heijmen RH. Cardiovasc Diagn Ther. 2023

## Rational 2: Natural angulation of the aortic arch

We take advantage of the **natural angulation of the aortic arch**, which will position the windows against the outer curvature



*Canaud L. JVS 2018. JVS 2020. JEVT 2022*

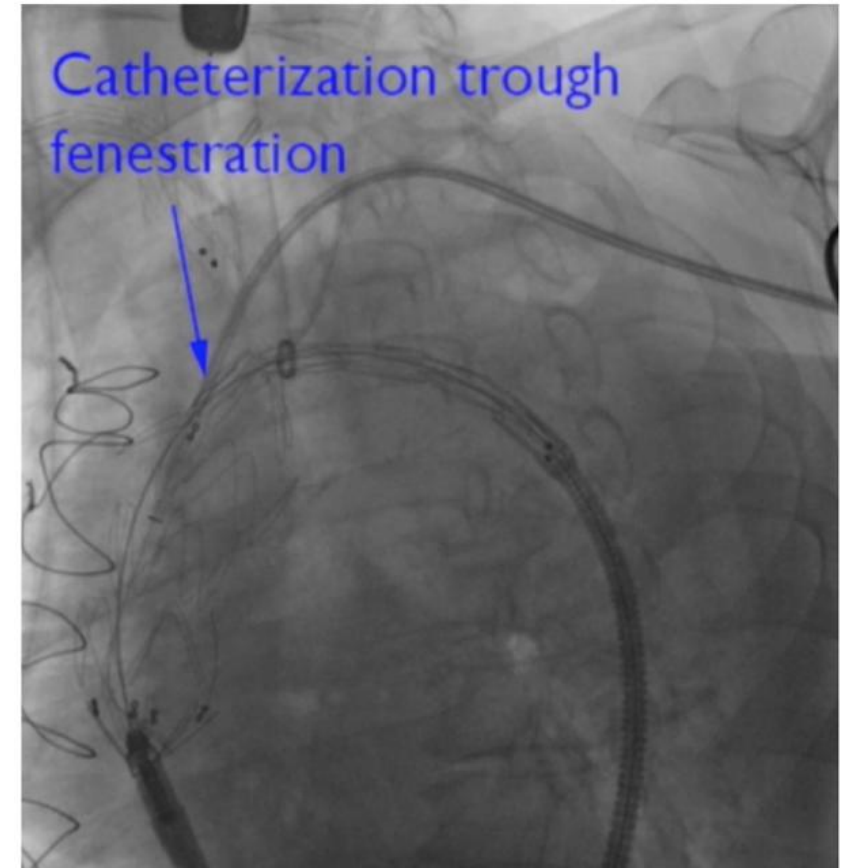
*Double homemade fenestrated stent graft for total endovascular aortic arch repair.*

## Rationale 3: no carotid manipulations / decrease aortic arch manipulations

**The specific feature of this double fenestrated device is its simple handling during operation:**

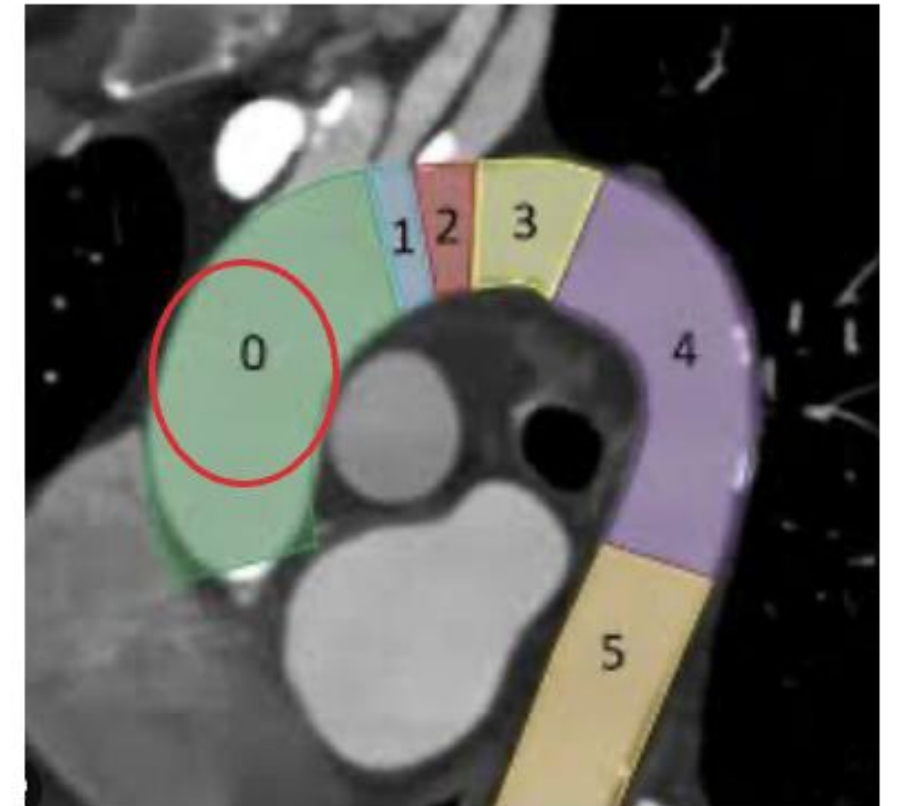
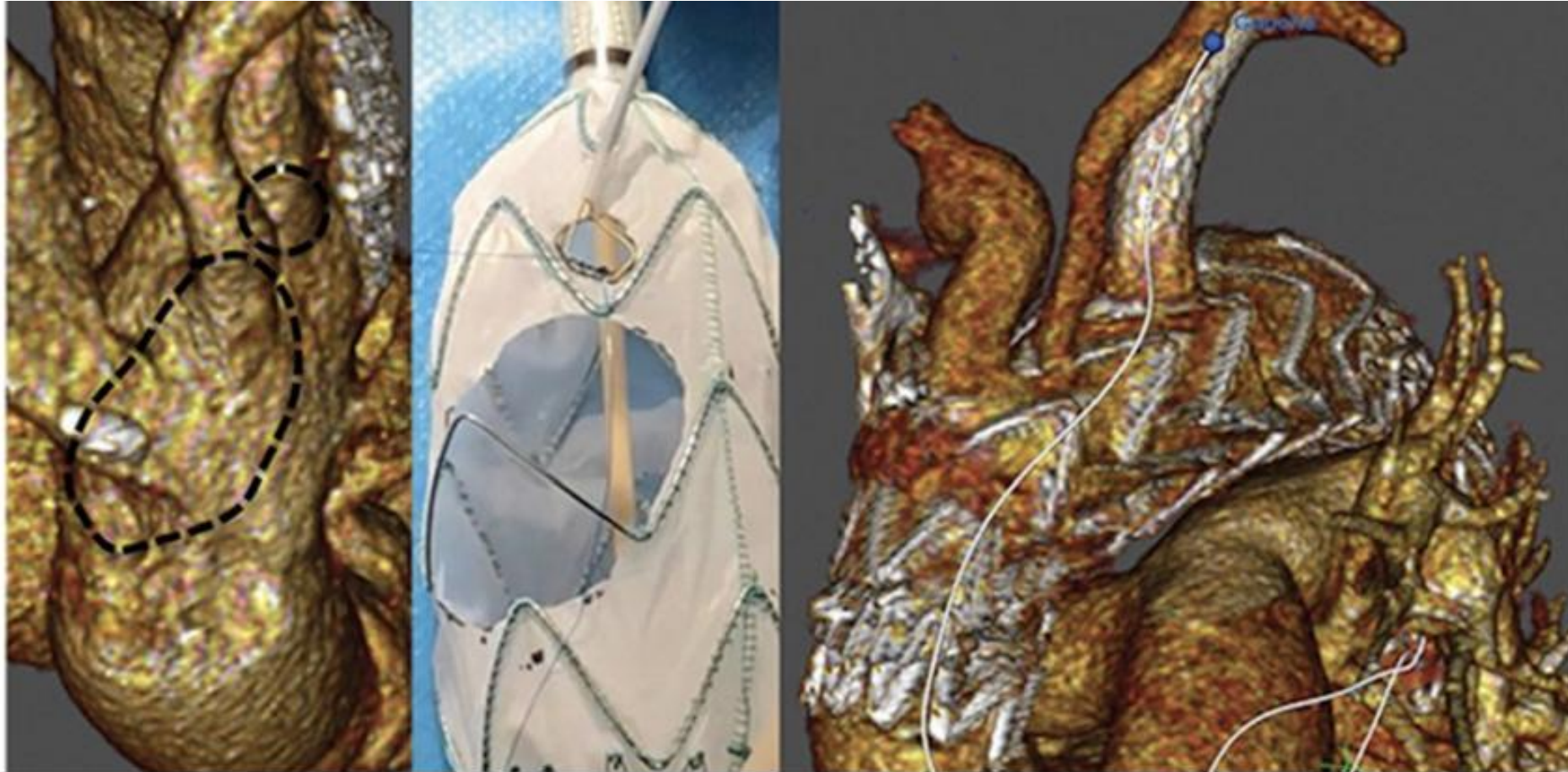
with the proximal fenestrations being directed to the orifices of the BT and LCCA automatically when LSA fenestration is catheterized and secured by covered stent placement

**No carotids manipulations: permanent stroke 2.2%**



*Canaud L. JVS 2018. Double homemade fenestrated stent graft for total endovascular aortic arch repair.*

## Rationale 5 : potential off-the-shelf solution?

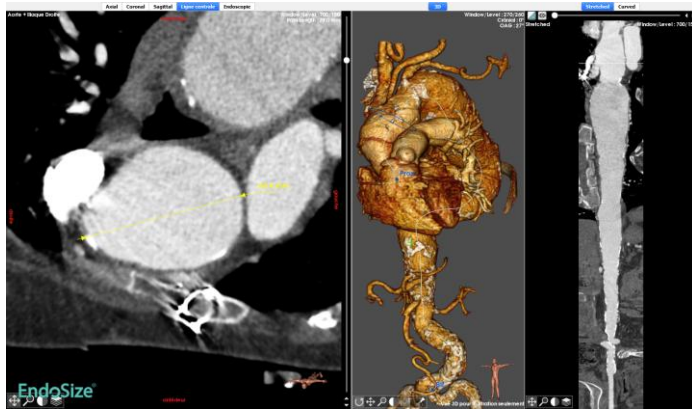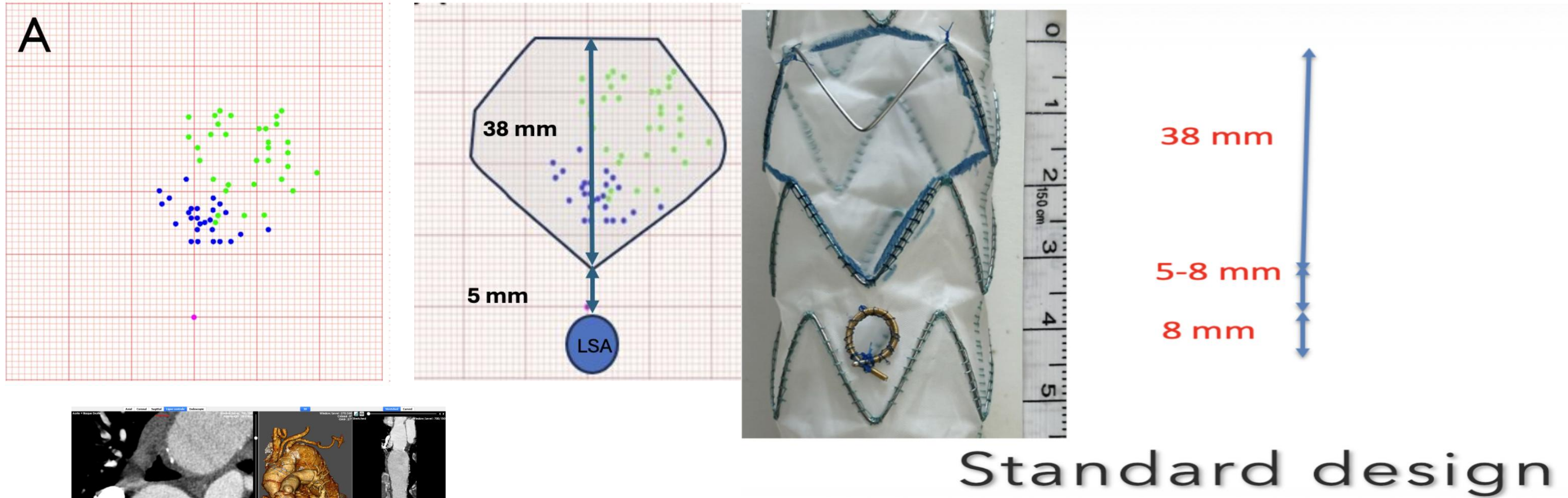


Chassin-Trubert L, Gandet T, Canaud L. *JEVT* 2019

20

*Double fenestrated stent-graft for aortic arch repair: a CT-based feasibility study.*

# Rationale 5 : potential off-the-shelf solution?



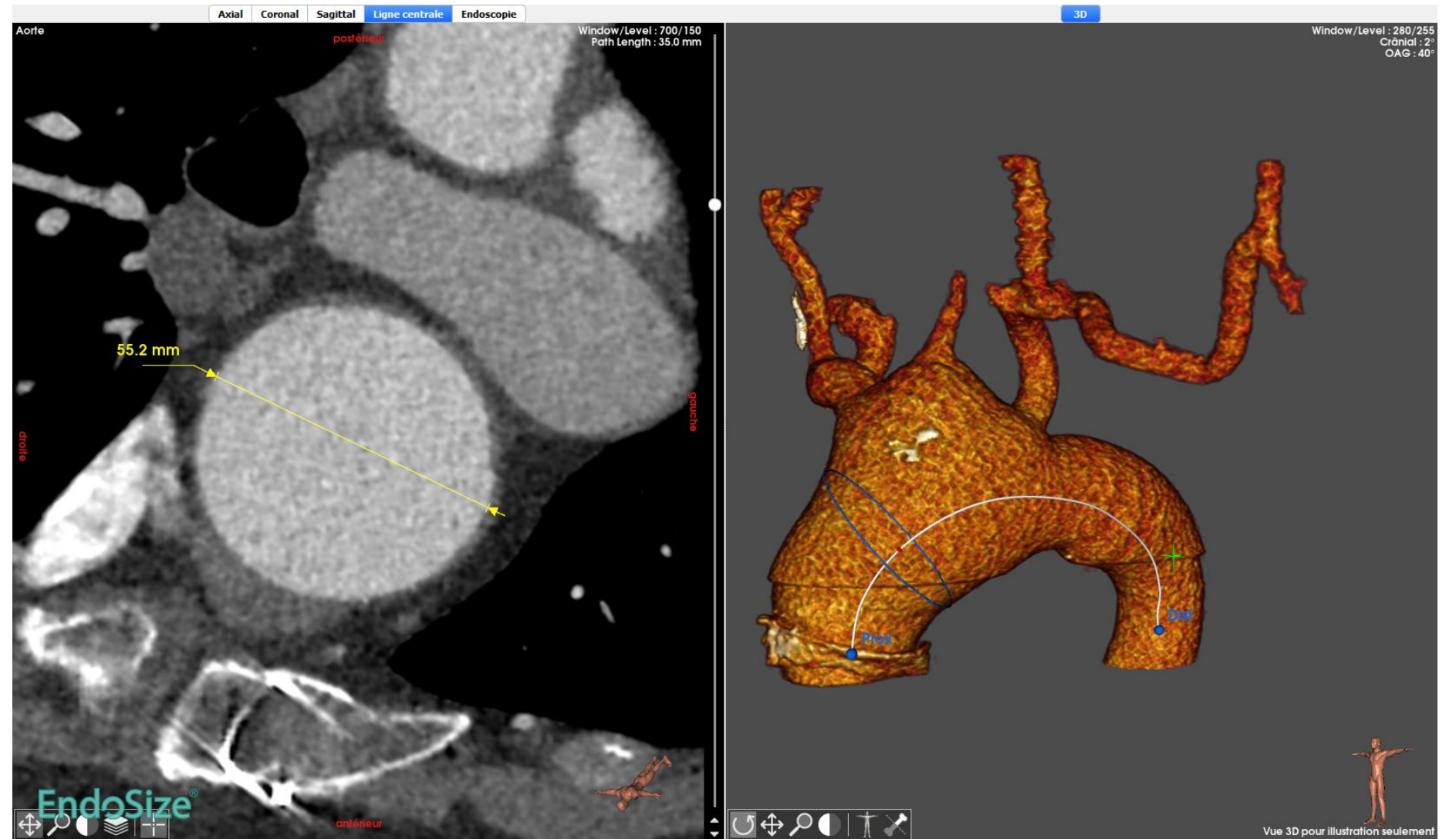
Chassin-Trubert L, Gandet T, Canaud L. JEVT 2019

Double fenestrated stent-graft for aortic arch repair: a CT-based feasibility study.

# Limitations

# Proximal neck

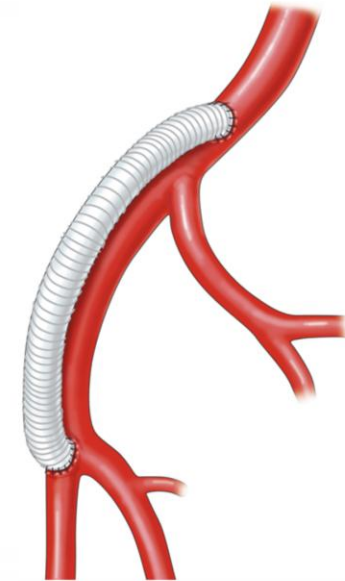
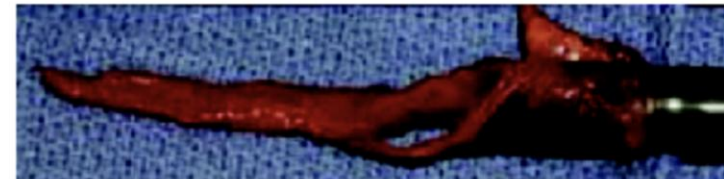
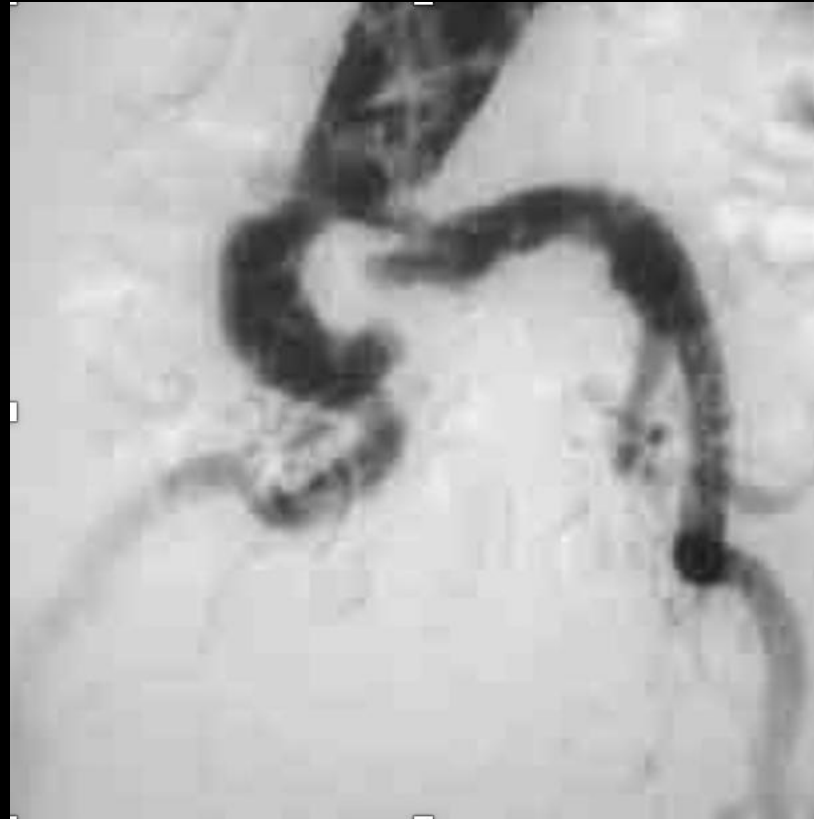- Maximum diameter:  
Just above the BT:42 mm
- Non eligibility:  
5 patients



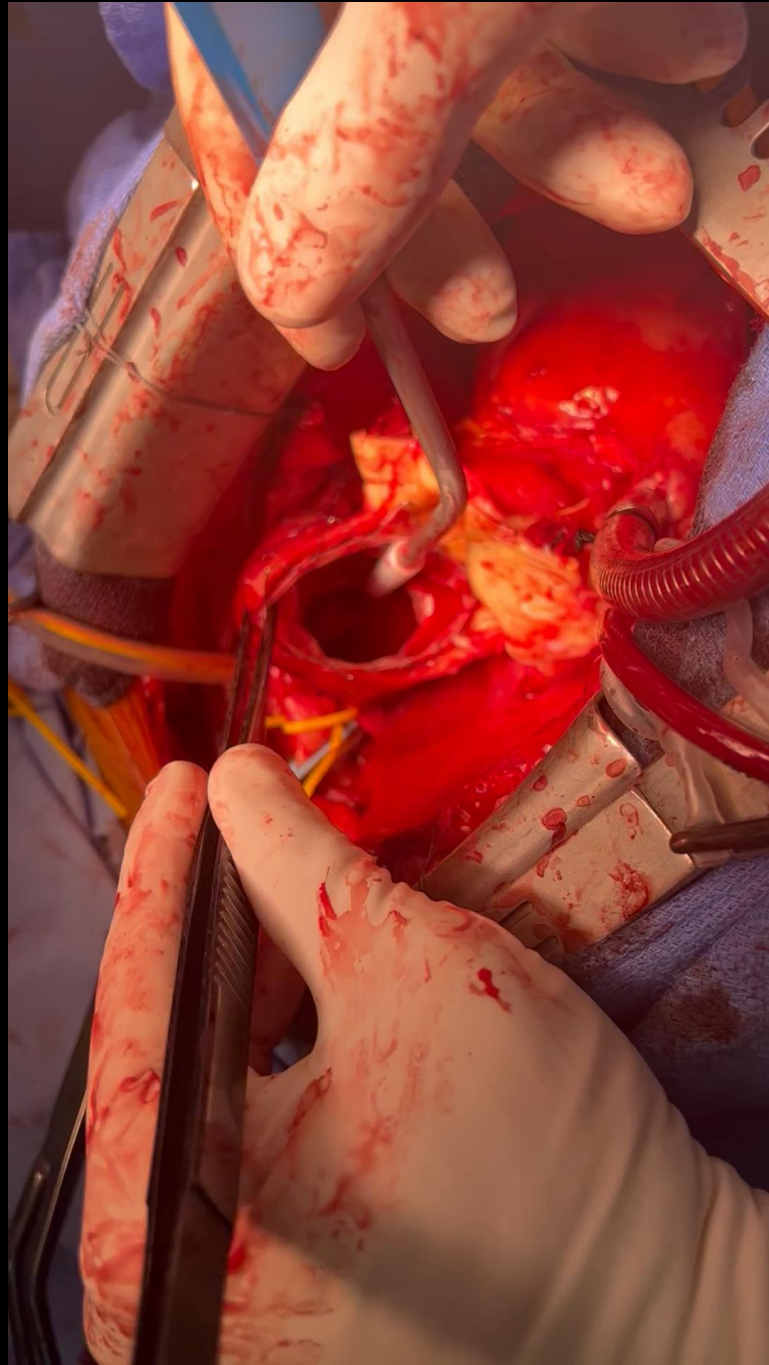
# Complications

# 1. Access

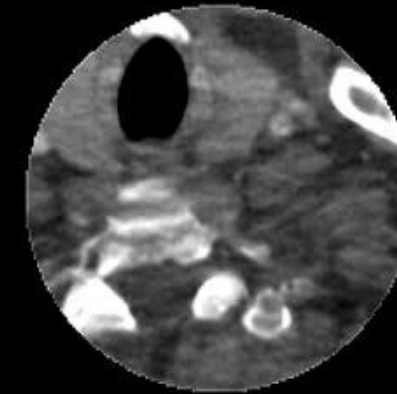
2 patients passed away of  
access related  
complications



## 2 Rtad



antérieur  
Window/Level : 700/150  
Position de la coupe : 136.25 mm



droite

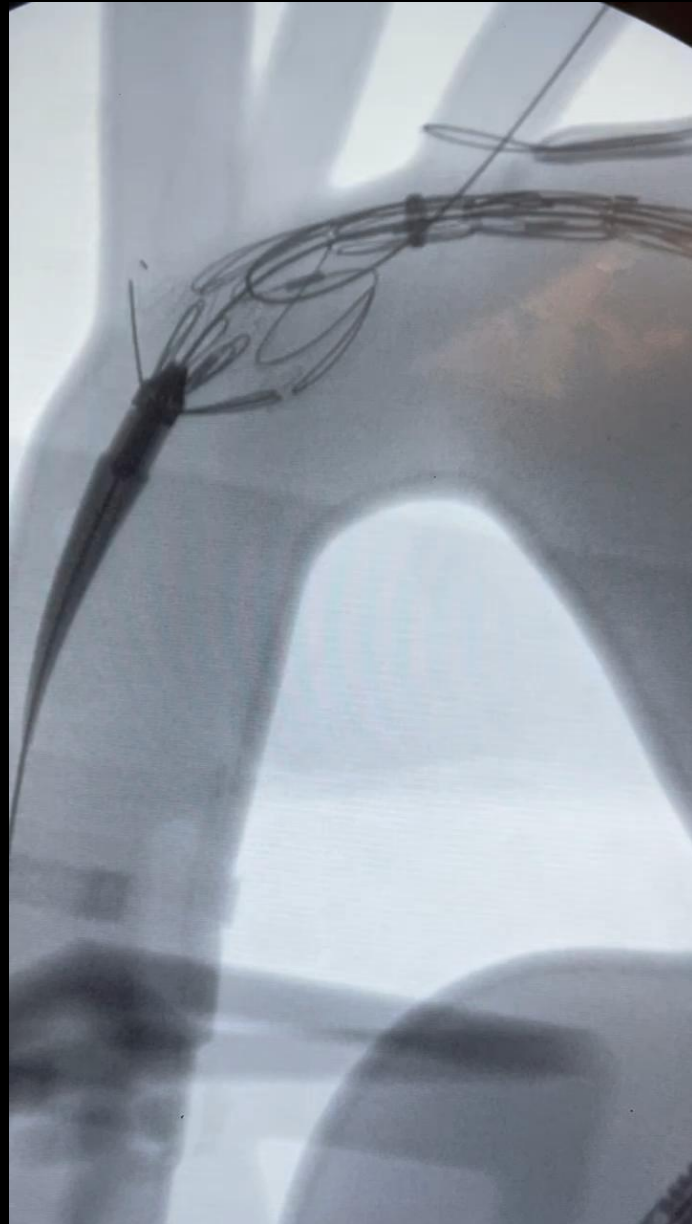gauche

EndoSize®

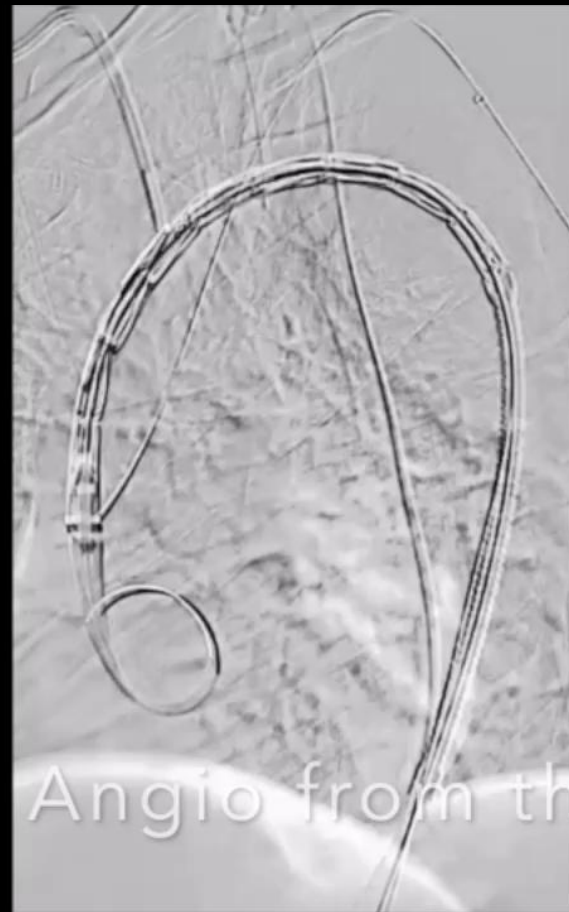postérieur



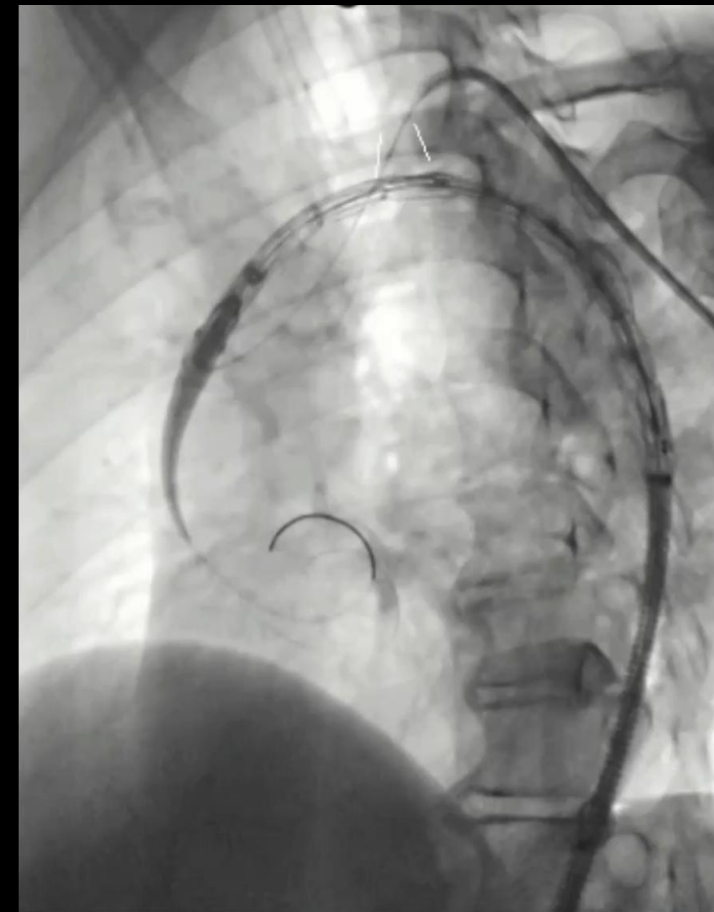### 3 Entanglement of the preloaded wire



### 3 Entanglement of the preloaded wire



Angio from the left arm



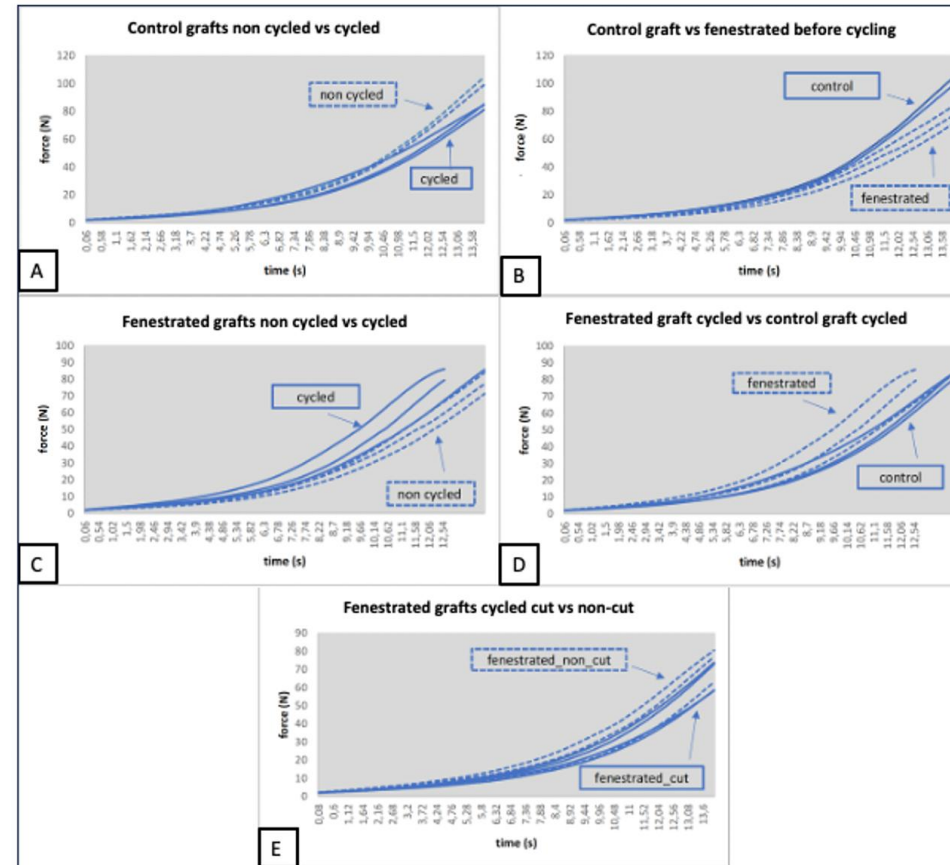
**Durability**

# Long-term outcomes

## Fatigability tests

- No graft failure
- 10 millions cycles

Figure 5: Comparison of graft's response after tensile strength testing



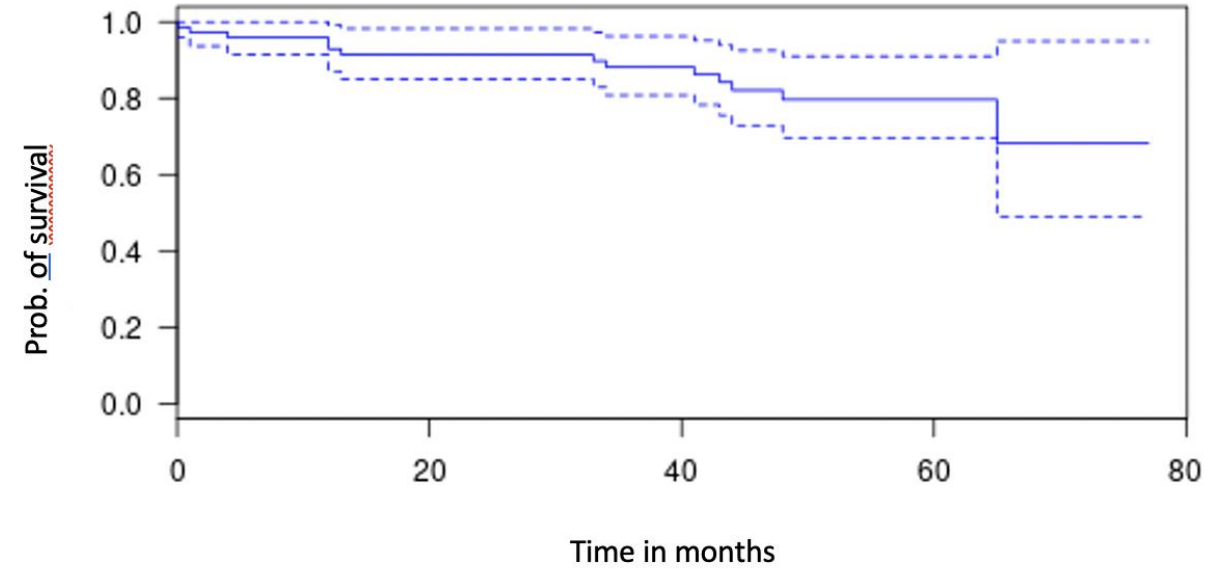
*Canaud L. Submitted JEVT 2024*

*Fatigability test for double fenestrated stent-graft*

# Long-term outcomes

## Minimum follow-up of 3 years for double fenestrated stent-graft: 74 patients

- No graft failure
- No conversion



Time (month)	0	12	24	36	48	60
Nb at risk	74	64	60	56	33	7

Figure 5 Survival curve of 74 patients after PMEG

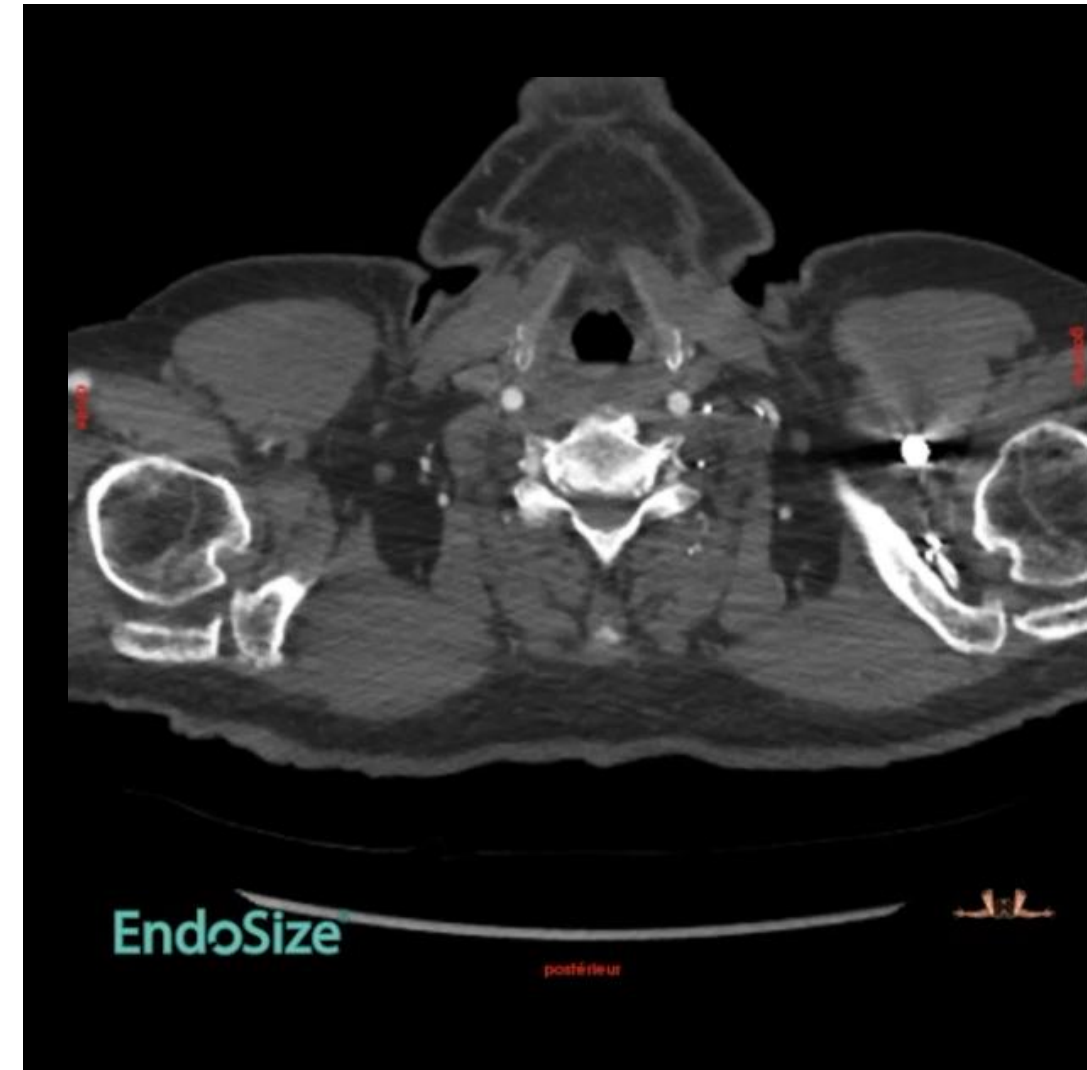*Canaud L. JVS 2024*

*Minimum follow-up of 3 years for double fenestrated stent-graft*

# Conclusion

# Conclusion

- **Simple procedure: The specific feature of this double fenestrated device is its simple handling during operation:** with the proximal fenestrations being directed to the orifices of the BT and LCCA automatically when LSA fenestration is secured by covered stent placement
  - *Fully percutaneous*
  - *1 hour*
  - *Decrease radiation exposure (divided by 100)*
  - *Vigilant sedation*



# Conclusion

- **Decreased stroke rate: no carotid manipulation/decreased manipulation in the arch : 1.7% mortality, 1% of type 1 endoleak, 1.7 persistent stroke**
- **No graft in the carotid arteries: no thrombus formation in the futur**
- **Confirmed by Evergreen so far**
- **Could be a potential off-the-shelf solution**

