

ciw

WORLD

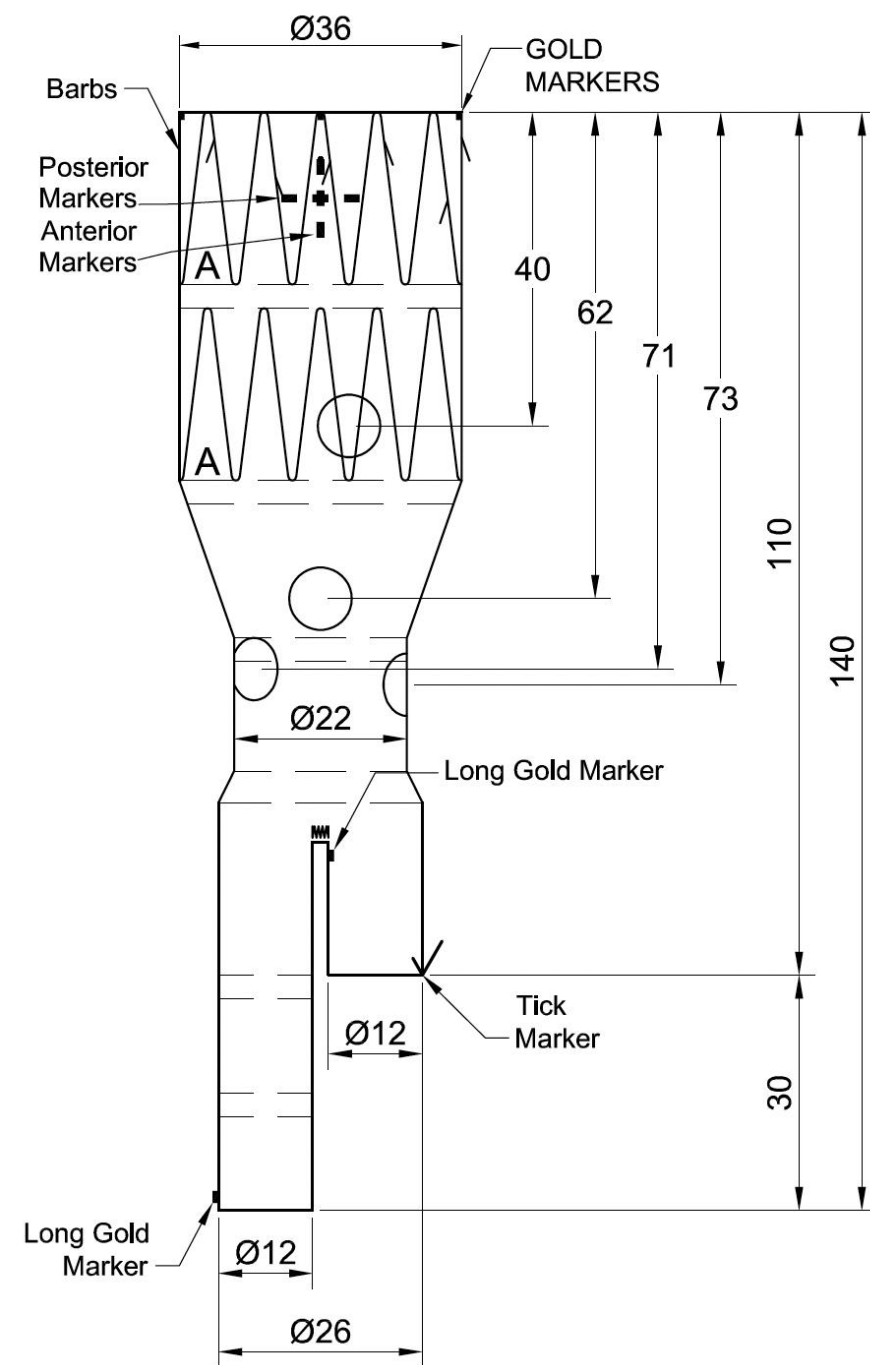

CHALLENGES & INNOVATIONS IN VASCULAR WORLD

31 MARS
1^{ER} AVRIL

2026

MÉRIDIEN ÉTOILE

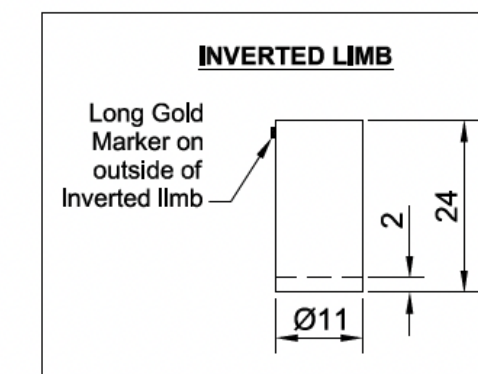
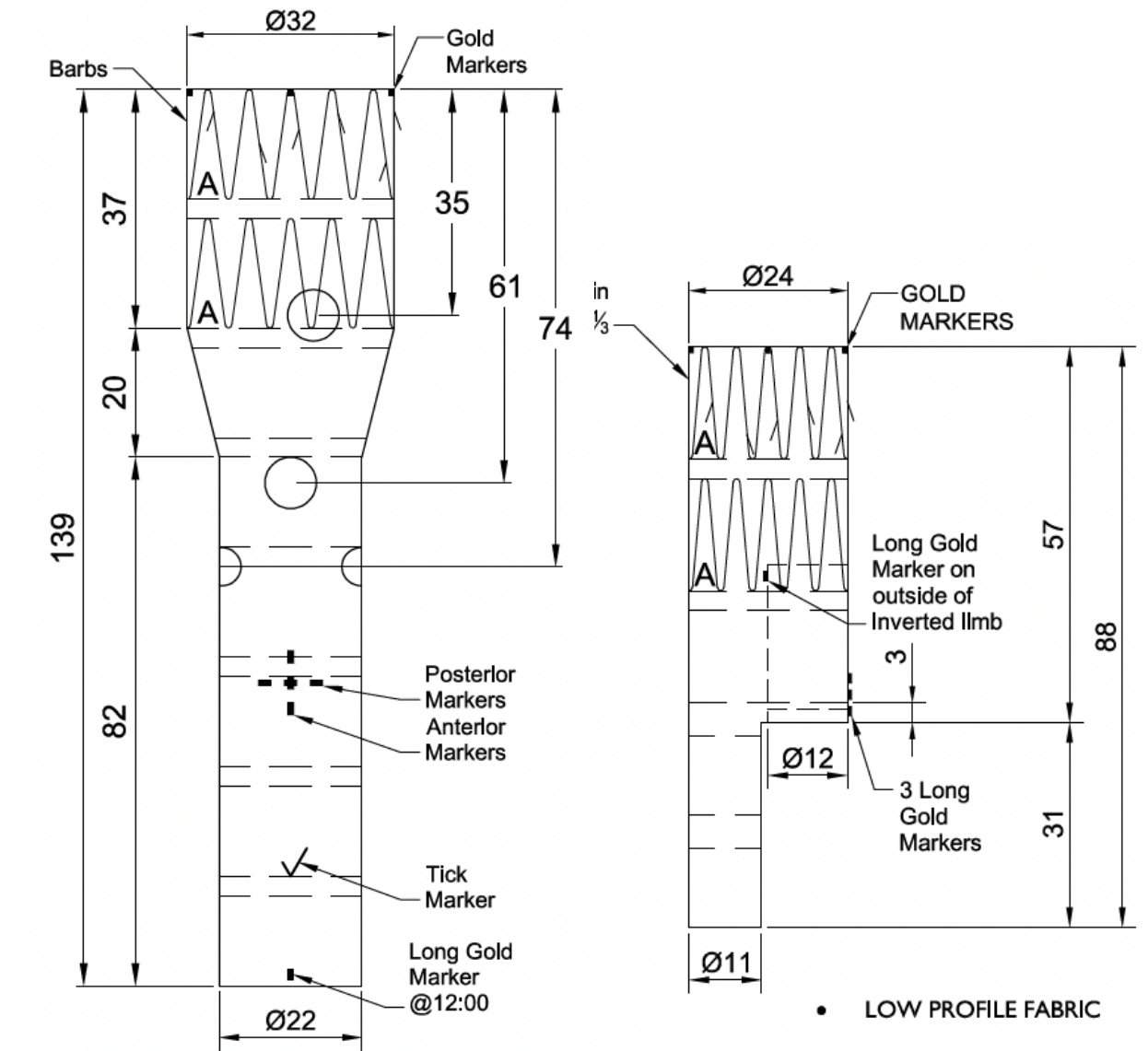
PARIS



Endoprothèses fenêtrées bifurquées

Branches invaginées


QUELS RESULTATS ?



Plus:
Ipsilateral Leg Extension
ZSLE-9-39-ZT


Contralateral Leg Extension
ZSLE-11-74-ZT

Conflits et liens d'intérêts



- Je n'ai aucun conflit d'intérêt potentiel à déclarer
- J'ai, ou j'ai eu au cours des deux dernières années, une affiliation, des intérêts financiers ou des liens d'intérêts de tout ordre avec les firmes suivantes, ou j'ai reçu des compensations financières ou des honoraires, des bourses de subvention ou de recherche émanant des companies suivantes :
 - **Consultant Cook Medical**

Disclosure Statement



- I do not have any potential conflict of interest

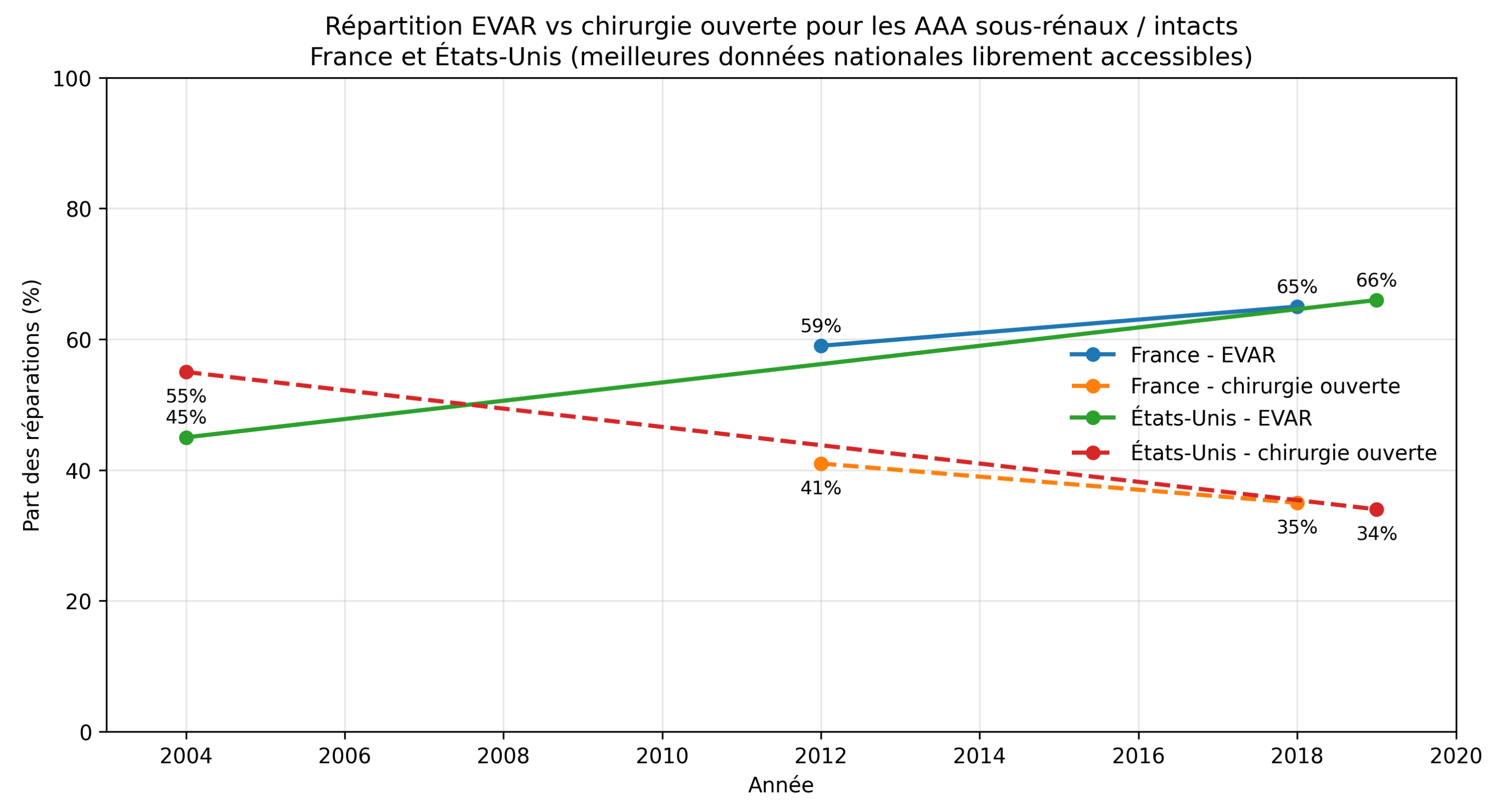
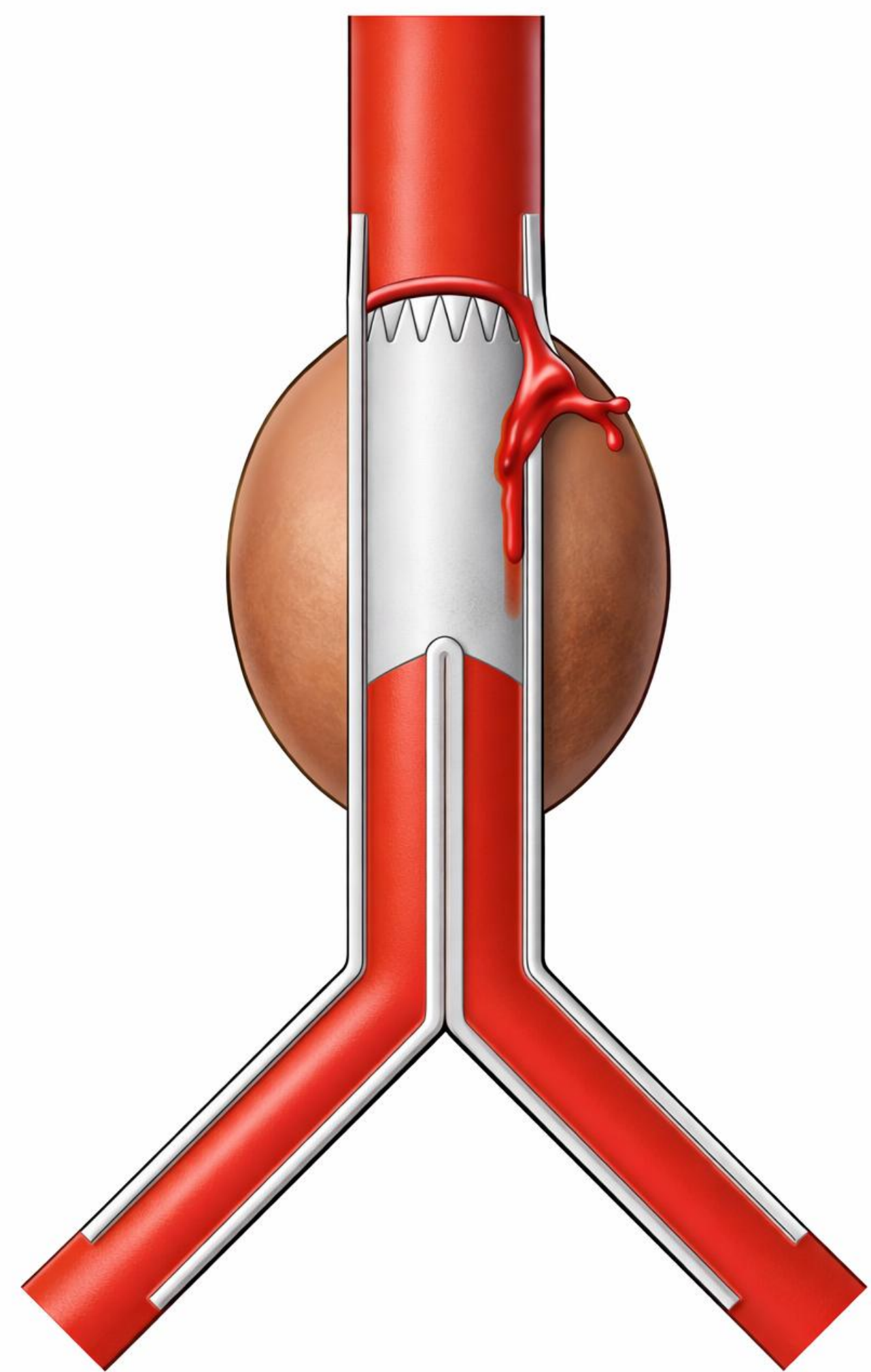
- I currently have, or have had over the last two years, an affiliation or financial interests or interests of any order with the following companies or I receive compensation or fees or research grants with the following companies:

- Consultant Cook Medical

De quoi parle-t-on ?

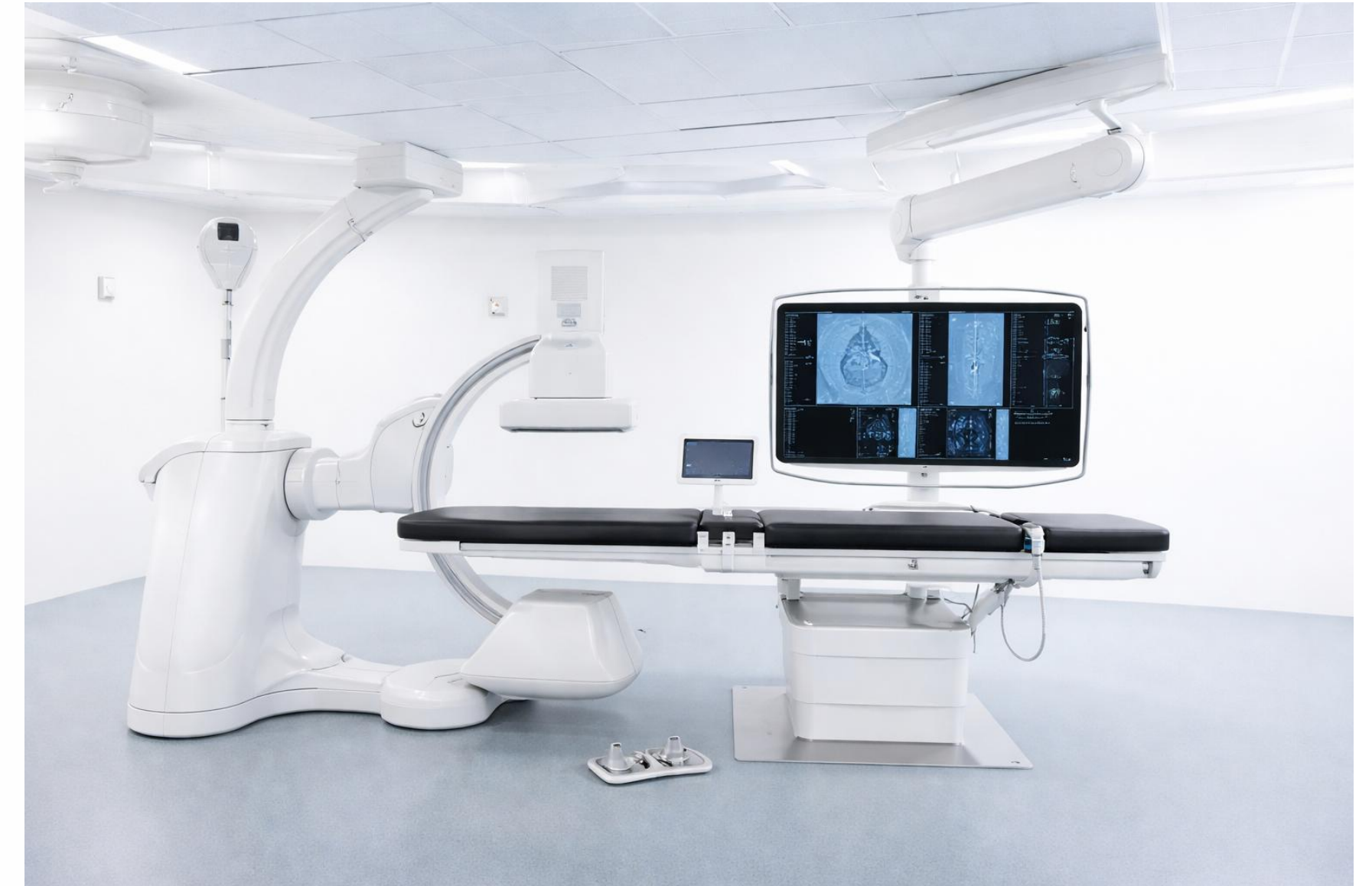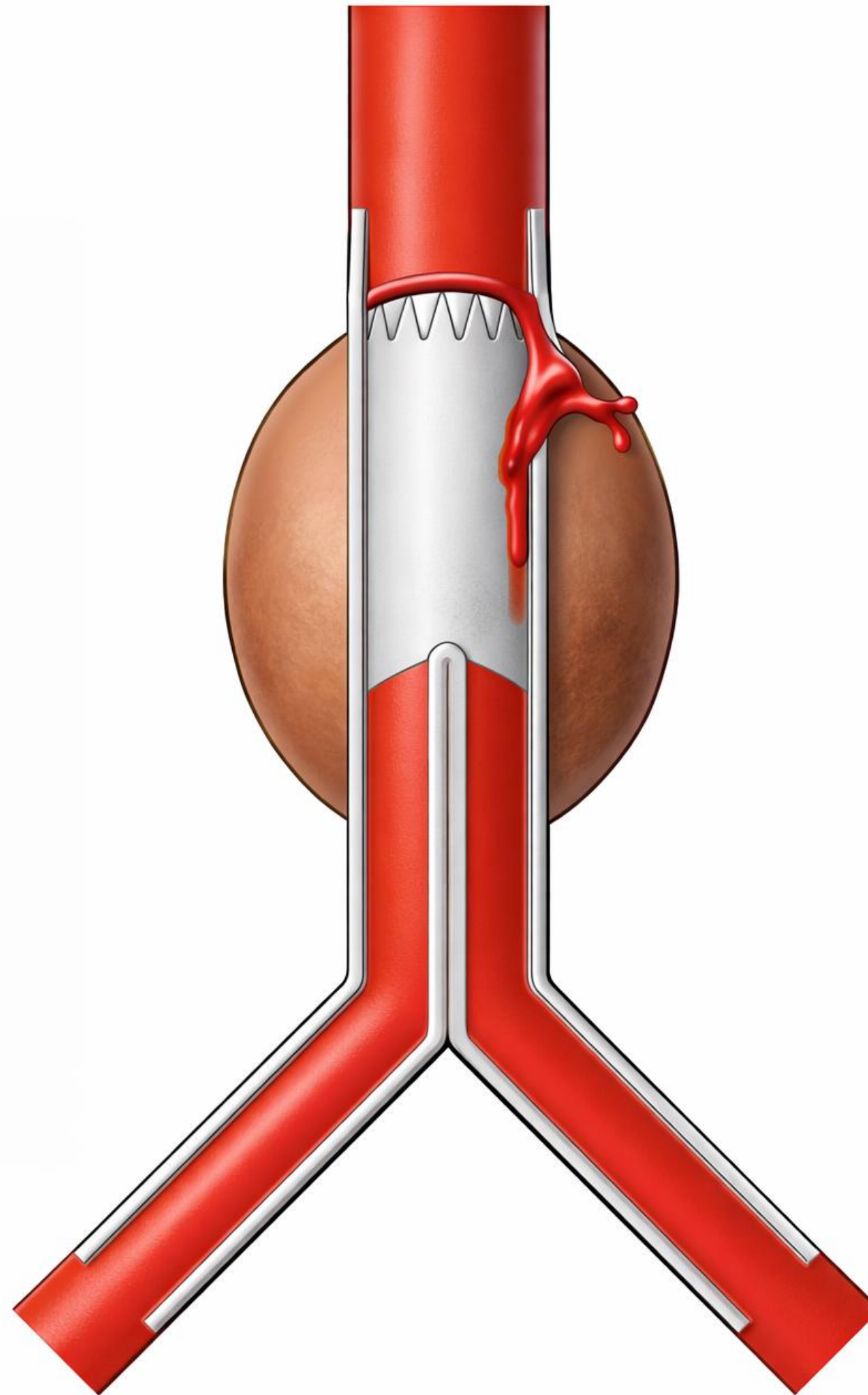
8% EF 1a 52 mois

Major et al. JVS 2022

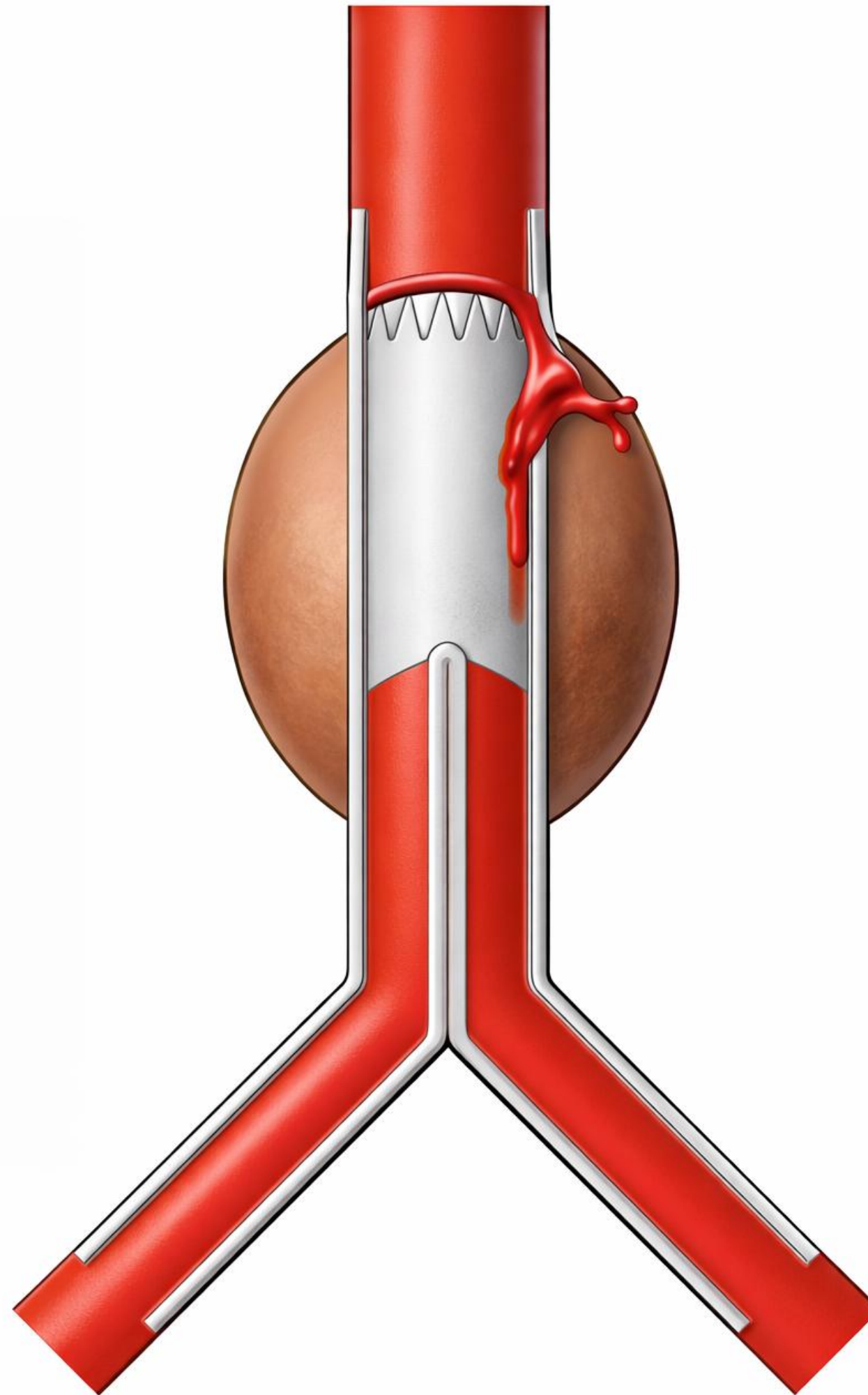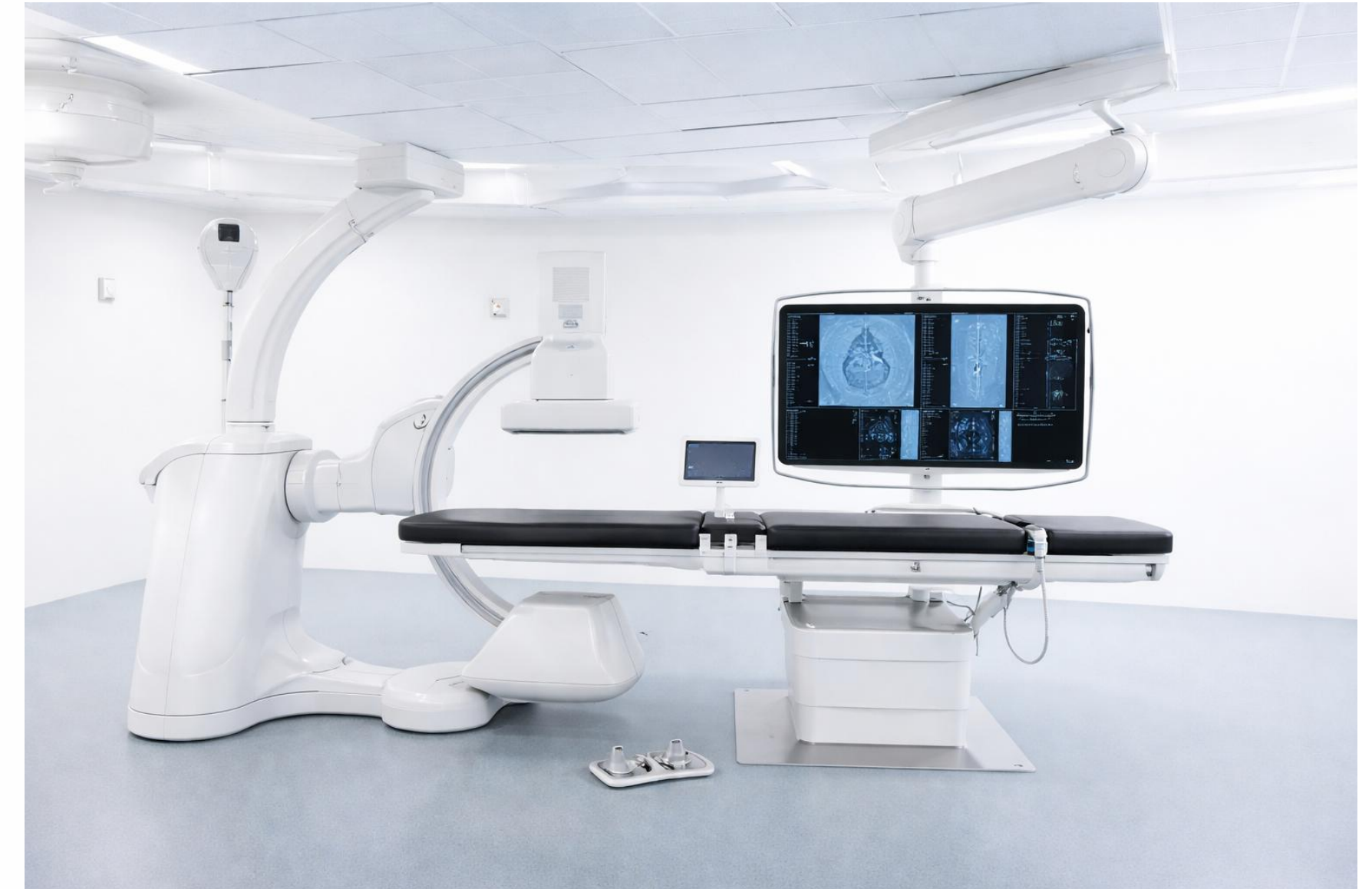


France: AAA non rompus, PMSI/SNDS, 59% EVAR en 2012 et 65% en 2018.
États-Unis: AAA intacts, Nationwide Inpatient Sample, 45% EVAR en 2004 et 66% en 2019.

De quoi parle-t-on ?


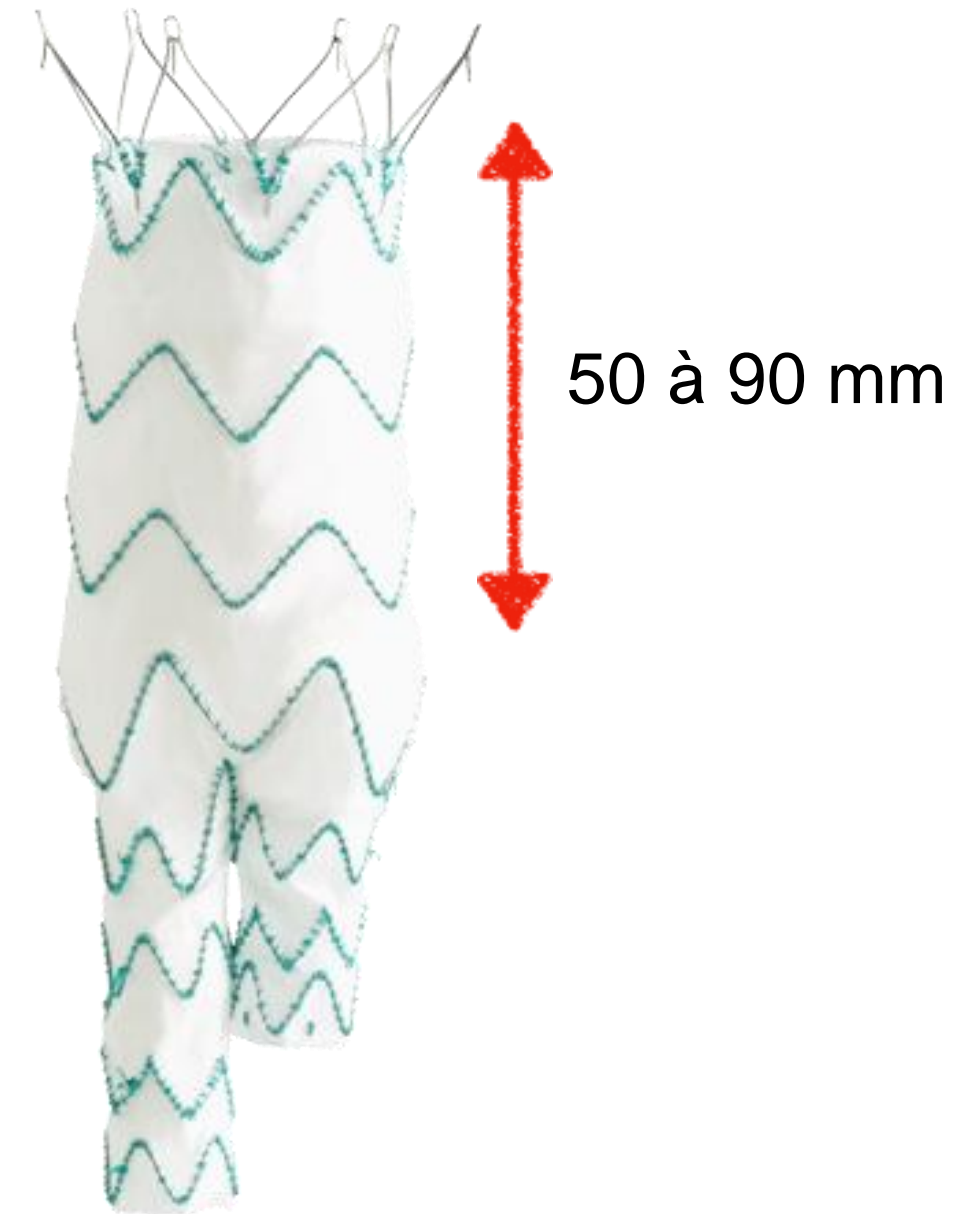
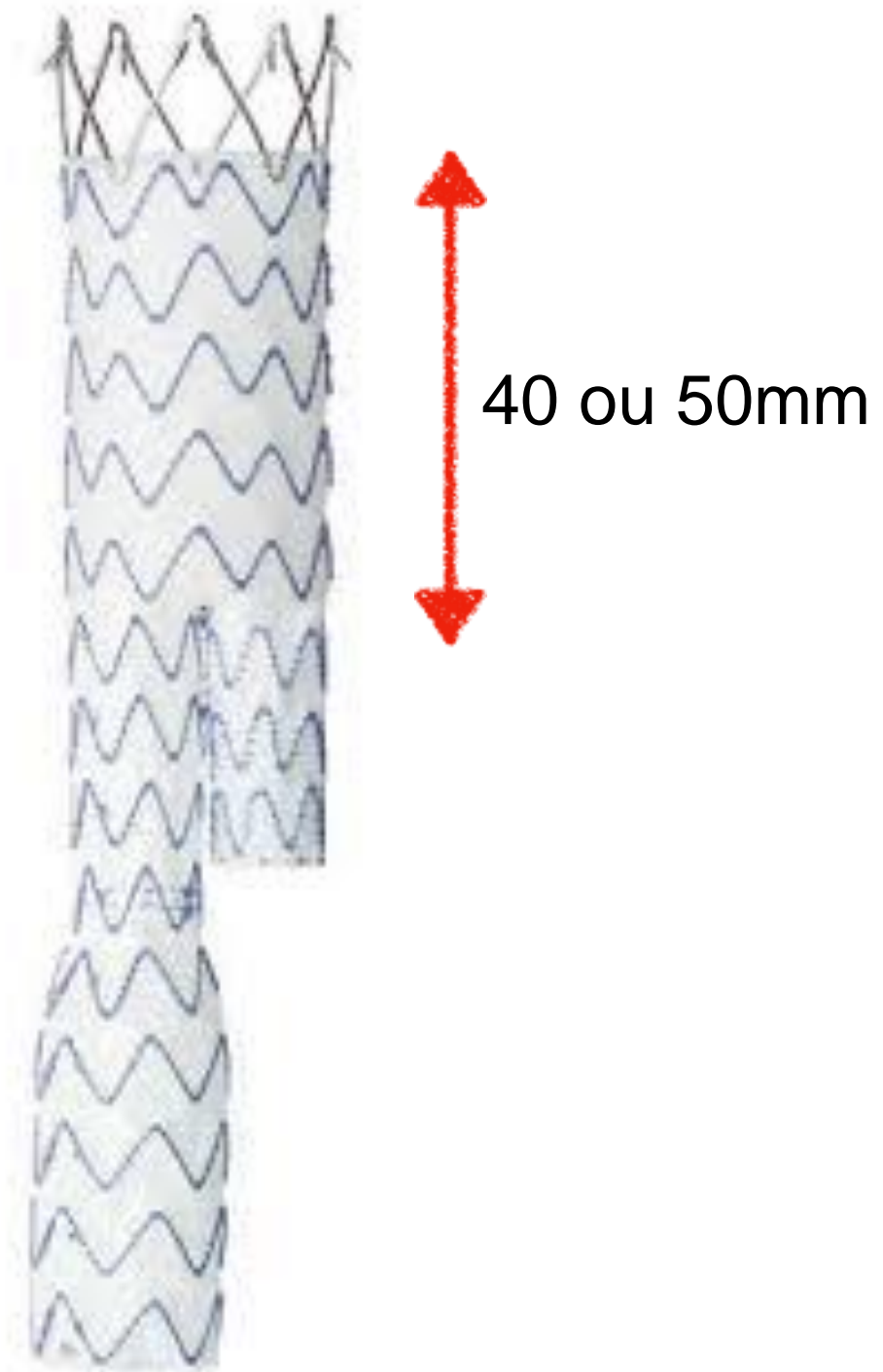
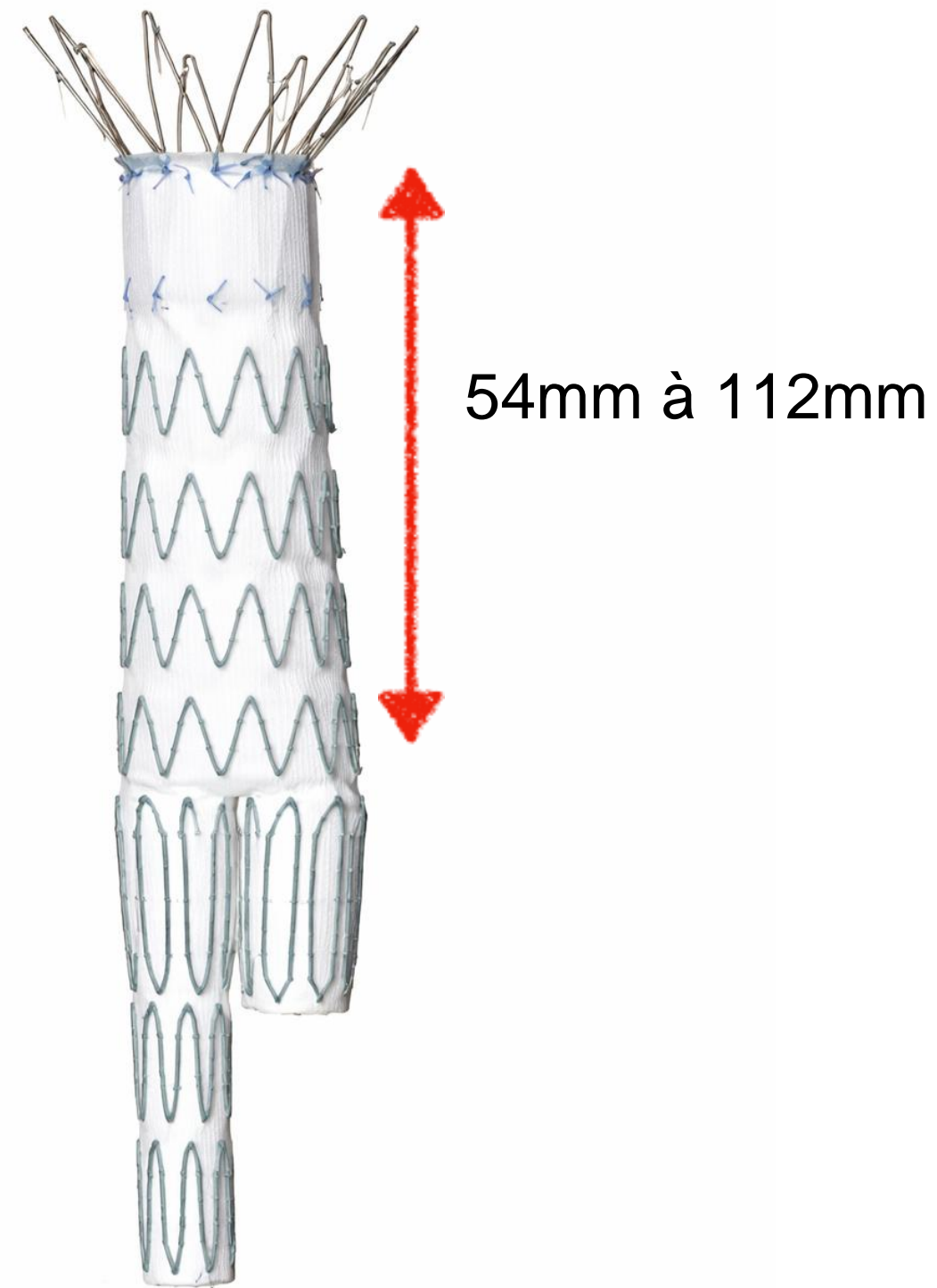


De quoi parle-t-on ?



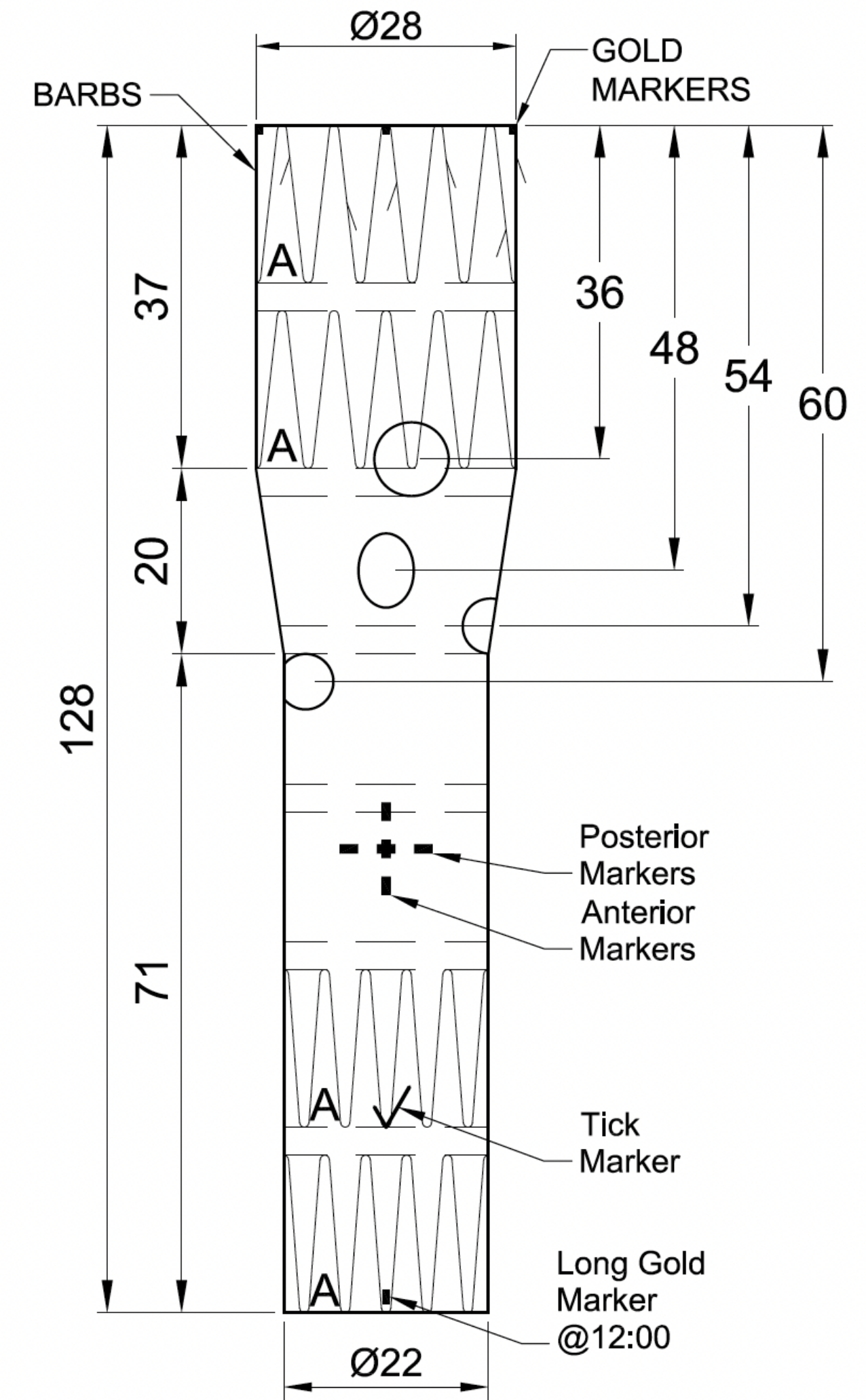
Recommendation 103			Unchanged
<p>Patients with Type 1 endoleak after endovascular abdominal aortic aneurysm repair are recommended for prompt re-intervention to achieve a seal, primarily by endovascular means.</p>			
Class	Level	References	ToE
I	B	<p>Antoniou <i>et al.</i> (2015),⁷⁹⁰ Schlösser <i>et al.</i> (2009),⁷⁹² Doumenc <i>et al.</i> (2021),⁷⁹⁸ Budtz-Lilly <i>et al.</i> (2023),⁸⁰⁶ Rajendran and May (2017)⁸²⁰</p>	

Traitement Endovasculaire



Si > 55 mm = Cuff Fenêtrée

**mais il est préférable de reliner l'ensemble de l'endoprothèse*



JN Newman, Jamie
RE: Inverted limb
À : Raphael Soler

Boîte de réception - Raphael Soler CVM 2 mars 2026 à 09:3

Good morning Raphael,

I hope you had a nice weekend.

Generally anything less than 100mm of infrarenal length in any anatomy would be deemed short for a standard bifurcated distal body (ZFEND). At this point we would recommend the inverted limb of an incorporated distal body.

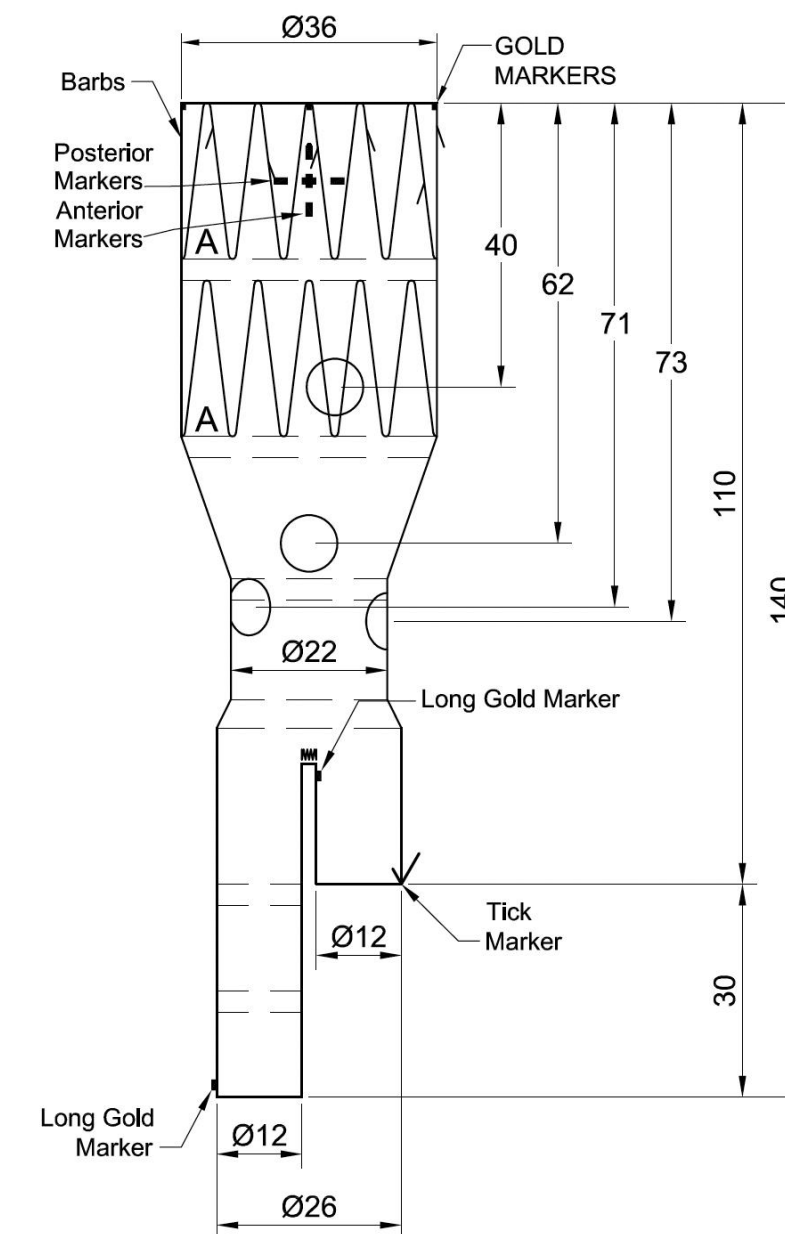
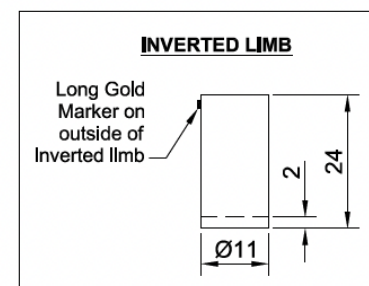
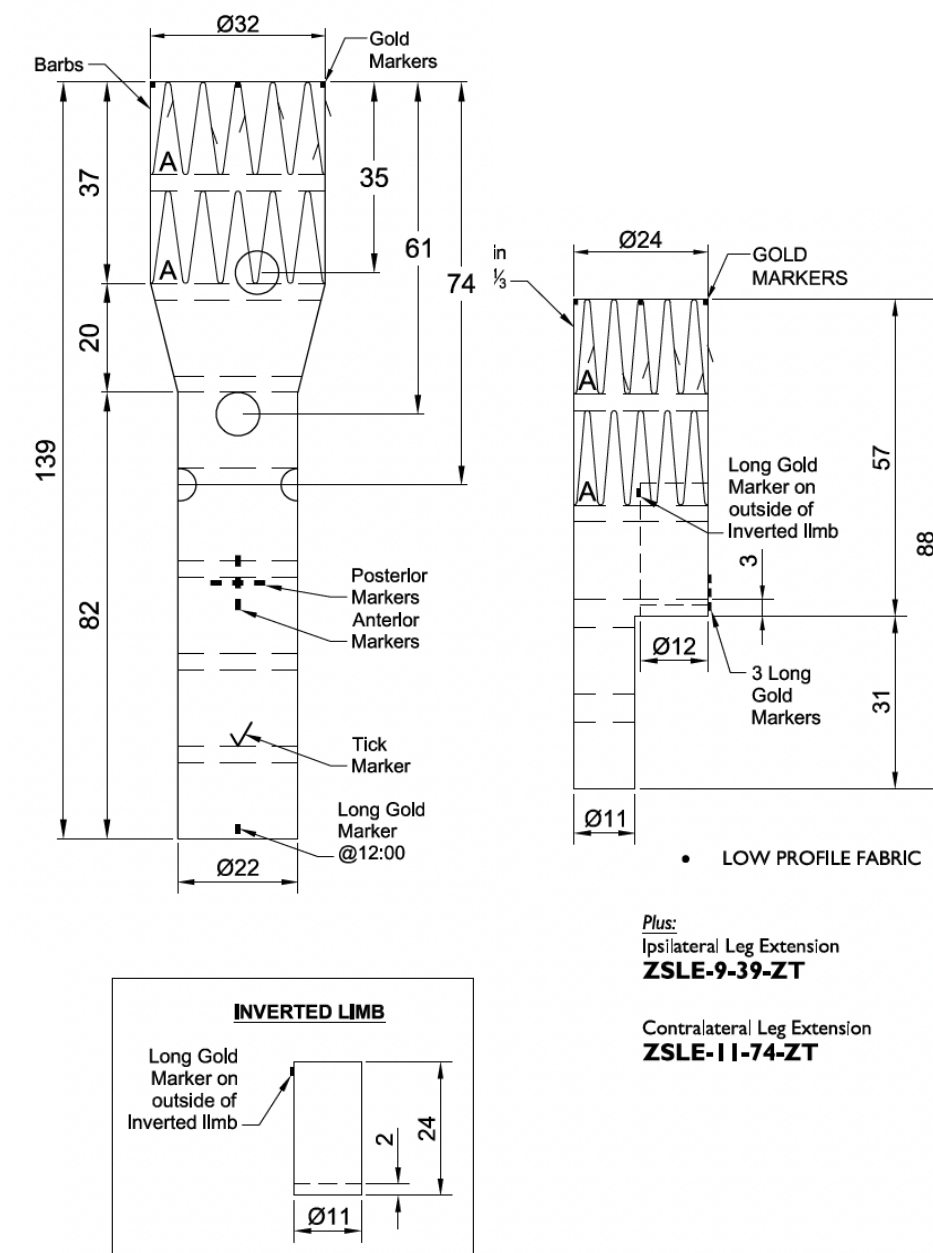
I hope this helps.

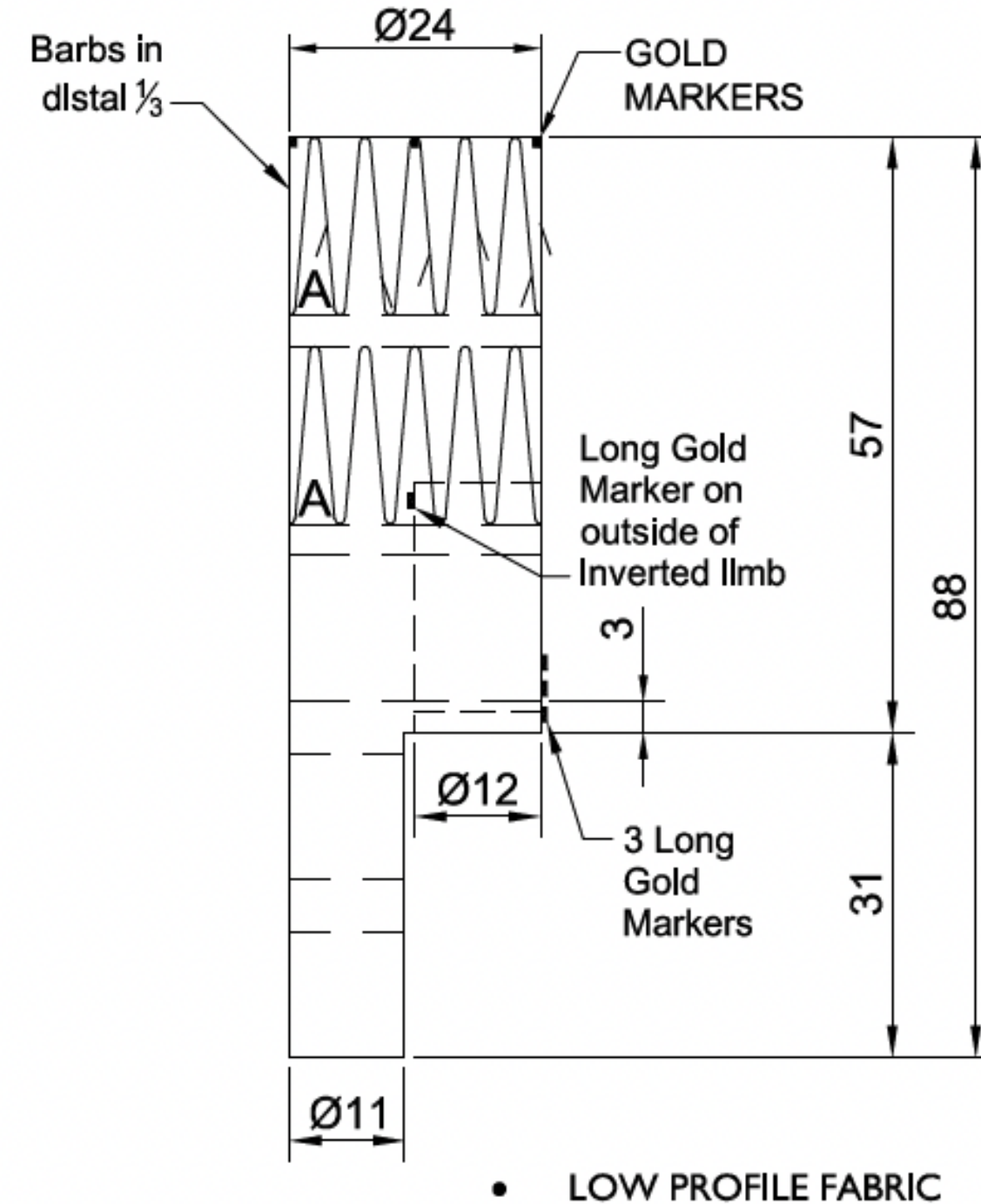
If you need any further information, please feel free to get in touch.

All the best

Jamie

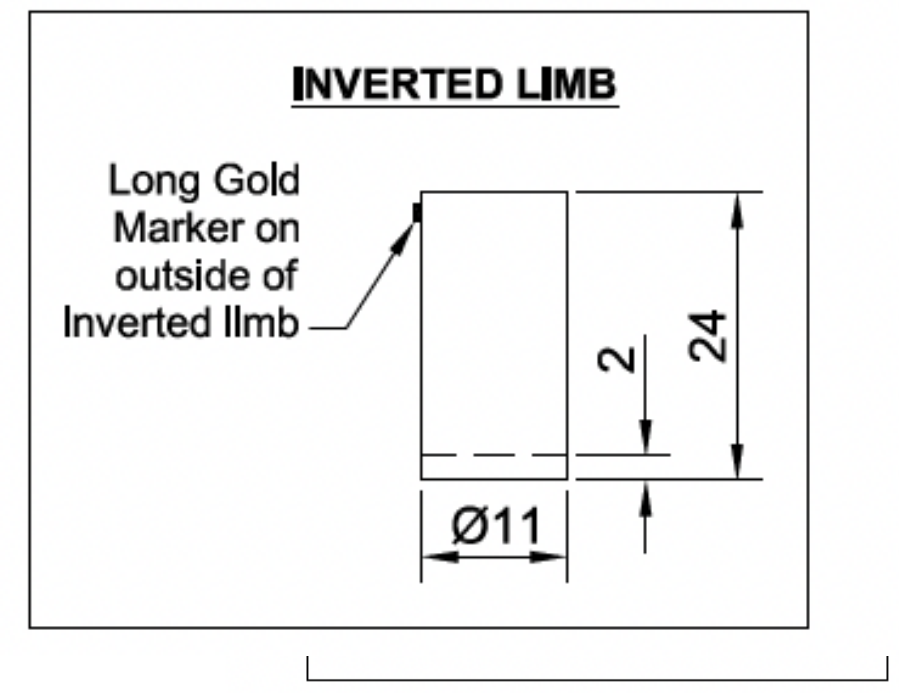
Jamie Newman
Endovascular Planner – EMEA Planning Services
Aortic Intervention, Vascular Division





Plus:
Ipsilateral Leg Extension
ZSLE-9-39-ZT

Contralateral Leg Extension
ZSLE-11-74-ZT



Multicenter Study > J Endovasc Ther. 2024 Jun;31(3):410-420.
doi: 10.1177/15266028221125158. Epub 2022 Oct 2.

Early and Mid-Term Outcomes of the Inverted Limb Configuration Below Fenestrated and Branched Endografts: Experience from Two European Centers

Cecilia Fenelli ^{1 2 3}, Nikolaos Tsilimparis ³, Gianluca Faggioli ^{1 2}, Jan Stana ³,
Enrico Gallitto ^{1 2}, Konstantinos Stavroulakis ³, Carlota Fernandez Prendes ³, Mauro Gargiulo ^{1 2}

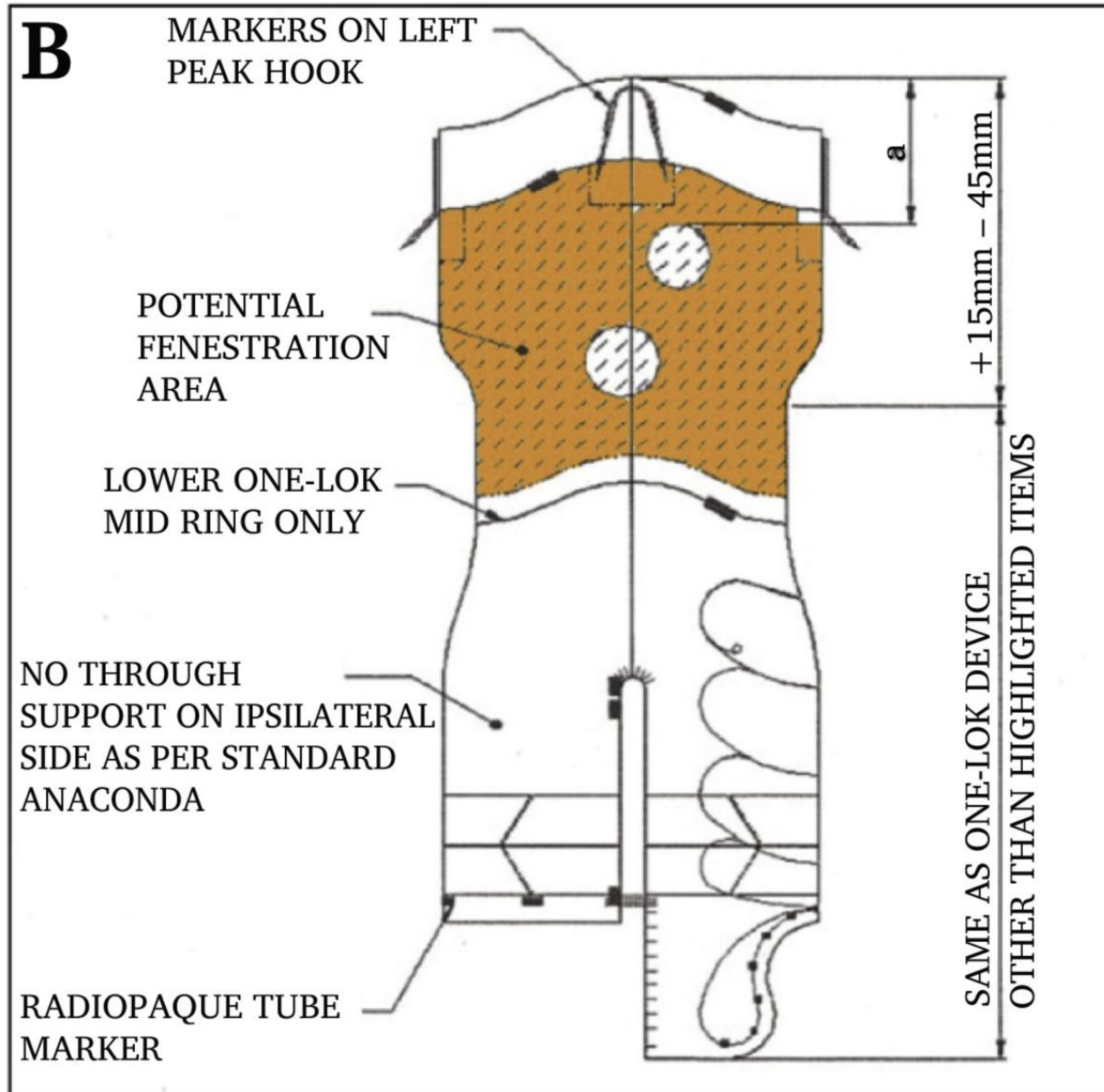
Succès technique 97,6 %

0% mortalité

architecture du module inverted limb 1 2 ou 3 stents

plus d'endofuite type III architecture 1 stent

MODULE FENETRE BIFURQUE



> [J Endovasc Ther. 2024 Apr;31\(2\):241-247. doi: 10.1177/15266028221119612. Epub 2022 Sep 12.](#)

Early Institutional Experience with One-Piece Bifurcated-Fenestrated Stentgraft in the Treatment of Abdominal Aortic Aneurysms

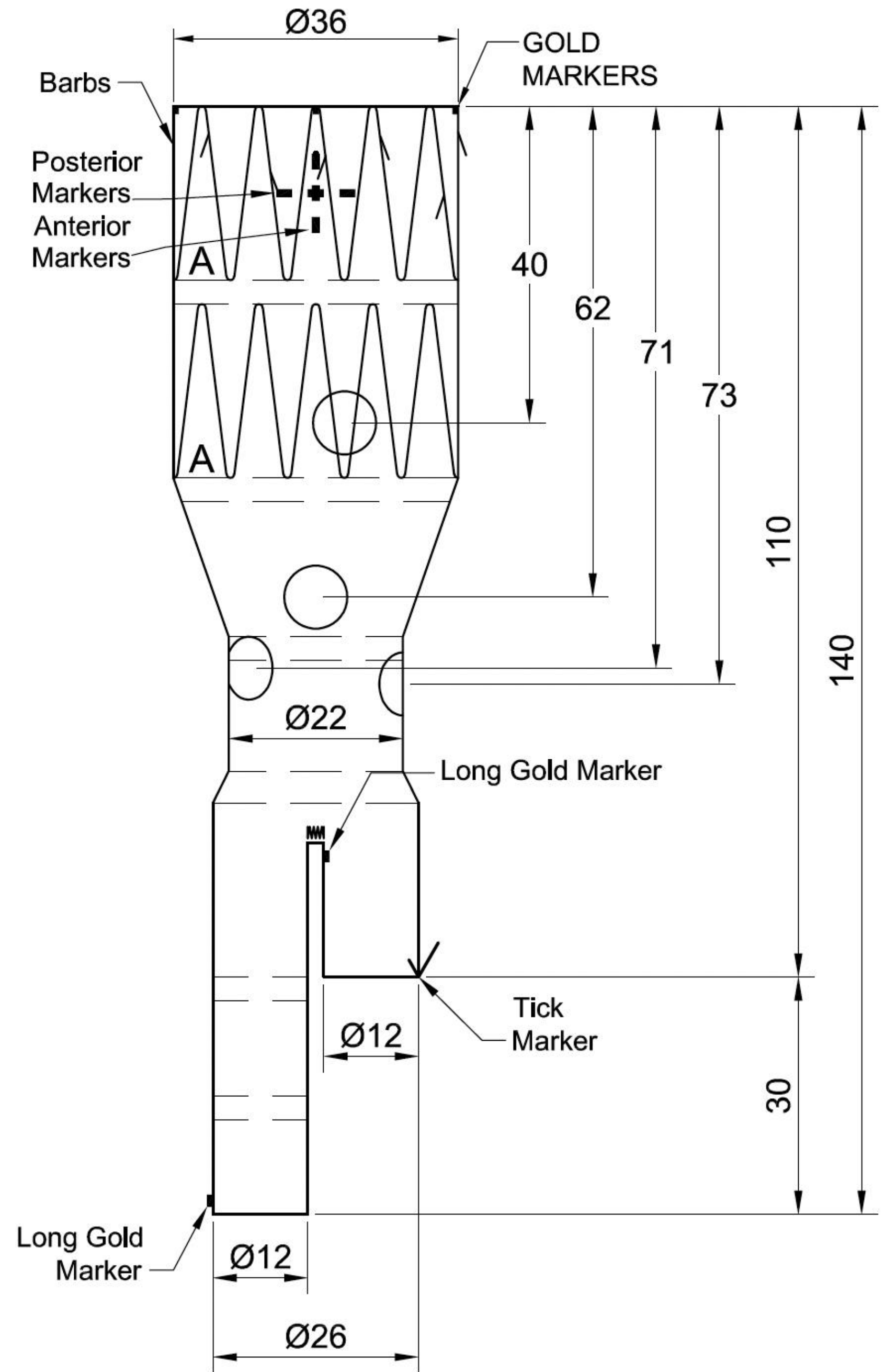
Thomas Mesnard ^{1 2}, Louis Pruvot ¹, Benjamin Oliver Patterson ³, Agathe De Prévile ¹, Richard Azzaoui ¹, Jonathan Sobocinski ^{1 2}

100% succès technique

0% MAE

Avantages

- ➔ Temps / Irradiation
- ➔ Endofuite type 3



Inconvénients

- Longueur prothèse
- Longueur lanceur
- Cathétérisme rénale opposée

Conclusion

« Toutes les anatomies »

Plus d'inverted limb

FEVAR bifurquée intégrée dans
tous les cas

Même dans les dossiers classiques

